

CHAPTER
110

Management of Non Variceal Bleed

R. K. Jain

Introduction

Non-variceal upper gastrointestinal bleeding (UGIB) remains a common and challenging emergency for gastroenterologists and general physician. The annual incidence is 50 to 150 per 100,000 of the population, and even though there have been significant improvements in endoscopic and supportive therapies, the overall mortality remains around 10%, and may even reach 35% in hospitalised patients with serious co-morbidity. Patients aged over 80 years of age now account for around 25% of all UGIB and 33% of UGIB occurring in hospitalised patients and therefore

Table I : Etiology of non-variceal UGI bleeding

Symptom	Frequency (%)
Peptic ulcers	50
Erosions	25-30
Mallory-Weiss tear	8
Watermelon stomach	3-5
Carcinomas	1-5
Angiomata	1-2
Dieulafoy's lesion	1-2
Hemobilia	<1
Aorto-enteric fistula	<1
Other	6-10

Adapted from gupta PK, Nonvariccal upper gastrointestinal bleeding . Med Clin North Am 1193;77:973-92

tend to account for much of the poor outcome of this condition.¹

Etiologies of non-variceal UGI bleeding

The major etiologies of acute non-variceal UGI bleeding are listed in Table 1. Peptic ulcer diseases accounts for most cases, followed by less Common causes including mucosal erosive diseases; Mallory-Weiss tears; gastric antral vascular ectasia (watermelon stomach); angiomas; tumors; and Dieulafoys lesions. Rare causes, such as hemobilia, aortoenteric fistula and vasculitis, must be considered in the appropriate clinical situation.

Although the commonly quoted figure of 50% for peptic ulcer bleeding may be overestimated. In a recent large CORI(Clinical Outcome Research Initiative) study of UGIB, peptic ulcer was the probable cause of UGIB in only 20% of cases.² The incidence of peptic ulcer disease is expected to continue to decline with more widespread helicobacter pylori eradication and proton pump inhibitor (PPI) usage.

The use of NSAIDs has been shown to be associated with an increased risk of ulcer bleeding in several studies;^{3,4} this risk increases with the use of conventional NSAIDs (versus selective cyclooxygenase-2 inhibitors), comorbid conditions,

Table 2 : Adverse clinical prognostic factors for UGI bleeding

Age greater than 60 years
Presence of comorbid medical condition
Onset of bleeding in hospital
Hemodynamic instability on presentation
Severe hemorrhage
Red nasogastric aspirate
History of hematochezia or hematemesis
Multiple transfusion (> 5)
Need for emergency surgical intervention
Continued or recurrent bleeding

concomitant use of steroids and anticoagulants, age, and prior history of gastrointestinal ulcers or complications.^{5,6} A recent meta-analysis found that both *Helicobacter pylori* infection and NSAID use independently and significantly increased the risk of ulcer bleeding; moreover, when both risk factors were present, their effect on the risk of ulcer bleeding was synergistic.⁷

Clinical presentation

Acute blood loss from the UGI tract is manifested in three ways: (1) hematemesis, (2) melena, (3) hematochezia, with the former two being most common. Hematemesis is the vomiting of blood, which can be either fresh, bright red, or “coffee-ground” in appearance. Melena is black, tarry, and characteristically foul-smelling stool, which results from the degradation of blood during its passage through the gastrointestinal tract. Melena can result from as little as 50 to 100 mL of blood in the stomach, but is more consistently produced with 1 unit of blood.^{8,9} Hematochezia (maroon or bright red blood per rectum) can be a presenting symptom in nearly 15% of cases of UGI bleeding.¹⁰ When arising from the UGI tract, hematochezia indicates more severe bleeding (at least 1000 mL of blood)⁸ and is associated with a worse prognosis.^{10,11,12}

Severity of the bleed is dependent on the size of the vessel affected. Simple oozing is caused by damage to small submucosal vessels less than 0.1 mm in diameter. More severe arterial bleeding

indicates a large vessel between 0.1 and 2 mm in diameter in the base of the ulcer has been eroded by the inflammatory process. Large ulcers arising from the posterior part of the duodenal cap can erode the gastroduodenal artery and provoke brisk bleeding.

Initial evaluation and Risk assessment

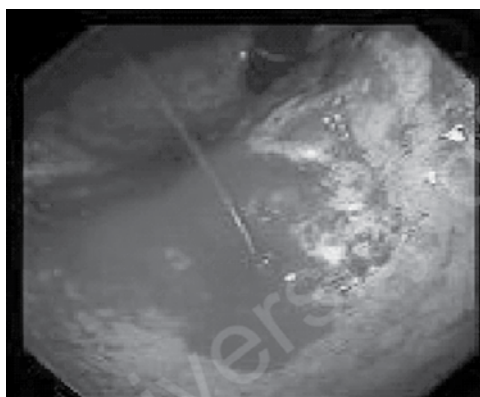
a. Pre endoscopic risk assessment : Clinical factors that are associated with poor outcome (Table-2) include hemodynamic instability on presentation; advanced age (> 60 years); presence of comorbid conditions; onset of bleeding in hospitals; hematochezia; red blood in the nasogastric lavage; and continued or recurrent bleeding.^{10,12-14}

Several clinical scoring systems e.g. Rockall score,¹³ the Baylor bleeding score,¹⁵ the Cedars-Sinai Medical Center Predictive Index¹⁶ and the Blatchford score,¹⁷ have been developed to direct appropriate patient management and enable cost effective use of resources. These systems weigh a combination of clinical, laboratory and endoscopic variables to produce a score that predicts the risk of mortality, recurrent hemorrhage, need for clinical intervention or suitability for early discharge. Factors commonly associated with poor outcome from UGIB may be related to the patient’s presentation and co-morbidities, or to the behaviors of the ulcer. Risk stratification using non-endoscopic parameters has been advantage that it can be performed readily on initial presentation in the emergency department, and appropriate initial risk assessment is still possible, even if early endoscopy, which requires skilled staff and resources, is not always available.

b. Value of nasogastric aspiration and lavage: Nasogastric aspiration and lavage have traditionally been standard procedures in the diagnosis and management of UGI bleeding. Iced saline gastric lavage, once considered essential for controlling UGI bleeding, has been shown to be ineffective in achieving

Table 3 : Forrest Classification (Modified) Stigmata of Haemorrhage With Risk Of Rebleed

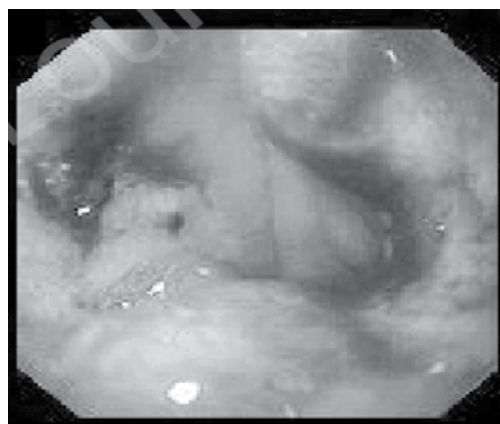
		Risk of Bleeding
Stage Ia	Spurting Vessel	70-90%
Stage Ib	Oozing Ulcer	70-90%
Stage IIa	Visible Non Bleeding Vessel	50%
Stage IIb	Adherent Clot	8-20%
Stage III	Flat Spot-Clear Base	< 5%

Figure 1

hemostasis and is no longer recommended.¹⁸⁻²¹

Nasogastric aspiration, however, may provide useful prognostic information. In the American Society for Gastrointestinal Endoscopy (ASGE) survey on UGI bleeding, a clear gastric aspirate on presentation was associated with a 6% mortality rate, compared with 18% when the aspirate revealed red blood, and nearly 30% when the aspirate and stool both contained red blood.¹¹

- c. **Timing of endoscopy** : It is now widely accepted that upper endoscopy is the best test for determining the location and nature of the bleeding lesion, and should be performed in virtually all patients presenting with UGI bleeding. Although the optimal timing of endoscopy has not been clearly established, early endoscopy within 12-24 hours has been advocated by most Gastroenterologists to achieve prompt diagnosis, provide risk stratification, and perform therapeutic hemostasis in high-risk patients. Low-risk patients may also benefit from

Figure 2

early endoscopy by safely avoiding unnecessary hospitalization.²²

- d. **Stigmata of recent hemorrhage (SRH)** : The modified Forrest criteria are internationally accepted for endoscopic risk stratification of peptic ulcer bleed, (Table-3). An actively bleeding ulcer is identified in approximately 5% to 25% of patients at the time of endoscopy, and is associated with continued or recurrent bleeding in over half of all cases.³ It is important to distinguish spurting hemorrhage (Fig. 1) from oozing hemorrhage, because the former is associated with a significantly higher risk of recurrent bleeding. The term “nonbleeding visible vessel” is used to describe a 2-to 3 mm protuberance in the base of an ulcer (Fig. 2). The protruding structure is usually not the vessel itself, but rather an adherent sentinel clot plugging the eroded artery.²³ The color of the protuberance may be predictive of rebleeding, with non pigmented lesion (white-pale) having a higher risk of rebleeding (71%) than red or purple lesion (38%).²⁴

Stigmata of recent hemorrhage

The NIH Consensus Conference also recommended therapy to ulcers with non-bleeding visible vessels as the risk of rebleeding approaches 50 per cent.²⁵ It is debated whether ulcers covered with blood clot (Fig. 3) should be treated or left undisturbed. Laine has shown that up to one-third of blood

Figure 3

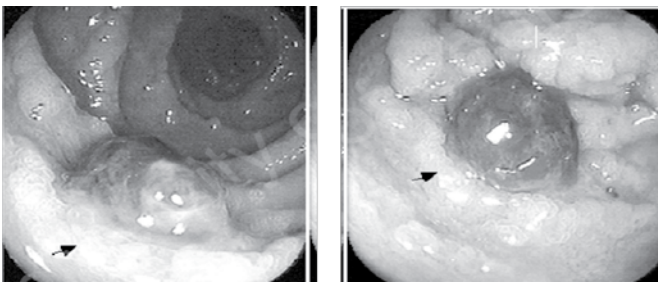
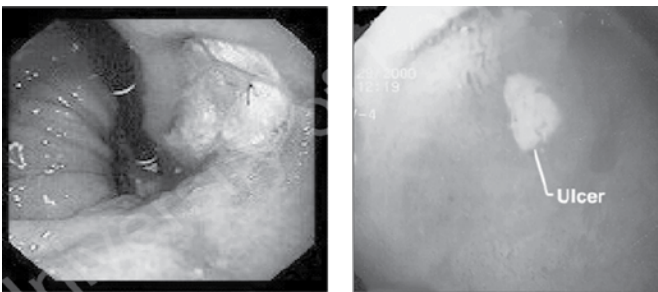


Figure 4



clot can be mechanically removed from ulcers to uncover major stigmata of recent hemorrhage²⁶. As benefits of treatment outweigh risk of complications we favor therapy. Ulcers clearly seen with flat pigmented spot or clean bases (Fig. 4) can be left untreated as they are associated with a low risk of further bleeding.

Endoscopic Therapy

Resuscitation including stabilisation of blood pressure & restoration of intra vascular volume and management of medical co-morbidities, often in intensive care, remains the mainstay of the initial management of patients prior to endoscopy. Endoscopic hemostasis is thus the key therapeutic tool for management of all high risk cases of non-variceal bleed. In two meta-analyses comprising over 30 randomized trials involving over 2400 patients, endoscopic therapy significantly reduced rebleeding, need for emergency surgery and mortality^{27,28}. Bolus administration of intravenous erythromycin prior to endoscopy has been shown to clear the stomach of blood, increase the likelihood of successful hemostasis and reduce the need for subsequent intervention.^{29,30}

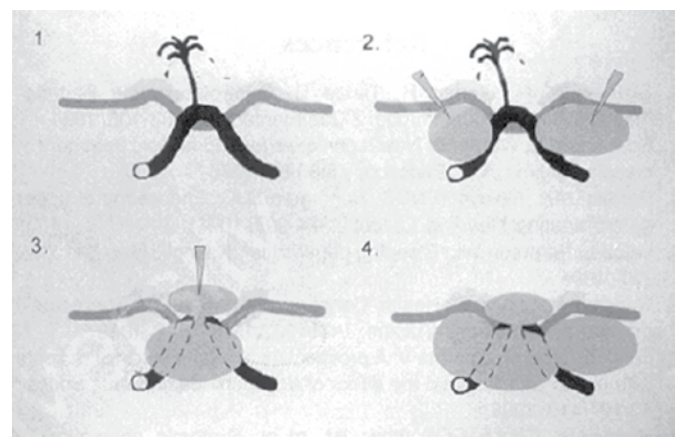
Table 4 : Endoscopic modalities available for management of UGI bleed

Injection	Thermal	Mechanical
Adrenaline	Heater probe	Hemoclips
Fibrin	Bicap probe	Banding
Human thrombin	Gold probe	Endoloops
Sclerosants	Argon plasma Coagulation	Staples
Alcohol	Laser therapy	Sutures

Hemostatic techniques available at the time of endoscopy could be classified as shown in Table 4. Selection of the optimal hemostatic device would depend primarily on the characteristics of the lesion, local expertise, and equipment availability and of course cost of the procedure.

Endoscopic Injection

Epinephrine : Diluted epinephrine (1:10,000) is the single most widely used agent. It causes vasoconstriction and promotes platelet aggregation without causing tissue necrosis or vessel thrombosis.^{31,32} Transfusion requirement, hospital stay and operative intervention are less with endoscopic injection of epinephrine.³³ Large volume can be injected without systemic effects except in patients with hepatic decompensation.³⁴ The hemostatic mechanism of epinephrine injection has been studied using normal saline, concentrated saline, 50 per cent dextrose, absolute alcohol and pure water, the result suggests that hemostasis results from tamponade by the solvent rather than by the effect of solute³⁴⁻³⁶. Because of its low cost,



simplicity and availability, epinephrine remains popular and forms the essential component of combination therapies.

Sclerosing agents : Ethanolamine, polidocanol and sodium tetradecyl sulfate are common sclerosants. Tissue necrosis is a problem when large volume is injected and hence they are usually used in combination with epinephrine injection³⁷⁻³⁹ after initial hemostasis with epinephrine, a sclerosant is targeted at the vessel. Sclerosants effectively stop bleeding but offer no advantage over epinephrine injection alone,⁴⁰⁻⁴² conversely major complications have been reported which raise safety issue in using sclerosants.⁴³⁻⁴⁴

Alcohol : The usefulness of alcohol has been confirmed by several groups in ulcers with active bleeding and non-bleeding visible vessel.⁴⁵ Like sclerosants, adding absolute alcohol to epinephrine offers no added advantages.⁴⁶ In practice, absolute alcohol causes tissue damage and is subjected to the same limitations as other sclerosants which limit their popularity.

Procoagulants (Thrombogenic Agents)

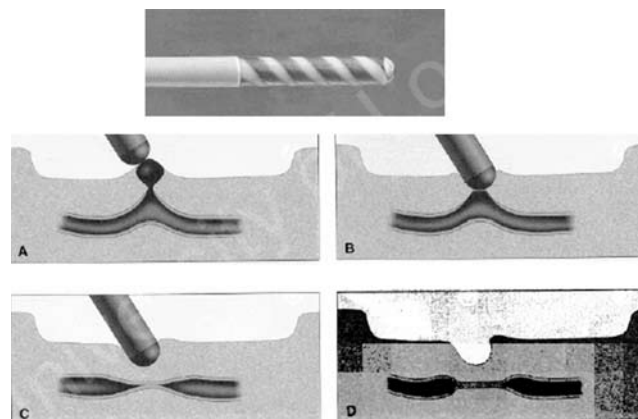
Endoscopic injection of fibrin or bovine thrombin with or without a second agent has been shown to achieve hemostasis in bleeding peptic ulcers. Repeated daily injection of fibrin glue following treatment with dilute adrenaline in patients with active bleeding or nonbleeding visible vessel until the ulcer base is clean or covered is expensive but reduces rebleeding although not mortality rates.⁴⁷

Thermal hemostatic devices

All thermal devices generate heat either directly (heater probe) or indirectly by tissue absorption of light energy (laser) or passage of electric current through tissue (multipolar probes, argon plasma coagulator). Heating leads to edema, coagulation of tissue protein and contraction of vessels resulting in a hemostatic bond.

Heater probe, bipolar and multipolar electric probes are commonly used thermal devices.⁴⁸⁻⁵⁰ Monopolar probe directs electric current through

the human body and is no longer used for safety reasons. The success of contact thermal devices is based on the principle of coaptive coagulation which practically requires: (i) forceful tamponade using a larger 3.2 mm probe. (ii) 15 to 25 watt power setting, and (iii) sustained coagulation with consecutive pulses for at least 8 seconds.



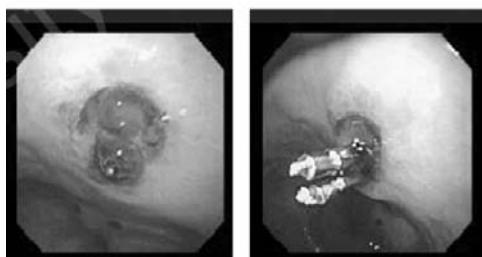
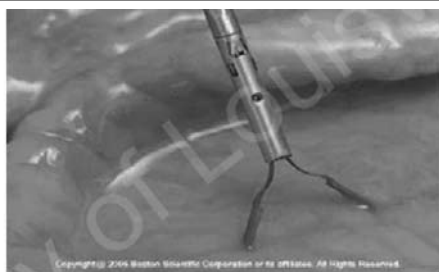The only non-contact thermal techniques currently available are Argon Plasma Coagulation (APC) and laser (ND: YAG). APC involves conduction of a high frequency electric current through a beam of ionized argon gas, resulting in superficial tissue damage and coagulation. A prospective observational study of APC in 254 patients with non-variceal UGIB revealed initial hemostasis rates of 75.9% and re-bleeding rates of 5.7%.⁵¹

The addition of a second hemostasis techniques increased successful hemostasis to 99.6%. The only comparative randomised trial involving APC alone with heater probe was underpowered, although rates of haemostasis, rebleeding, emergency surgery and 30 days mortality were similar for the two techniques.⁵² APC is especially useful for diffuse bleeding arising from a large area, bleeding owing to coagulation disorder or tumor bleeding. It has been used successfully to treat gastric antral vascular ectasis (GAVE),⁵³ angiodysplasia and hemorrhagic telangiectasia. Treatment of bleeding ulcers with APC does not appear to confer any advantage over the heater probe for endoscopic haemostasis. ND : YAG laser therapy has been shown to be as effective than injection with adrenaline-polidocanol,⁵⁴ but,

due to technical constraints of the technique, laser therapy is not routinely used in the management of non-variceal UGIB.

Mechanical hemostasis

Mechanical hemostasis with endoloops or clips, e.g. the Hemoclip has an increasing role in the control of non-variceal UGIB. Endoclip are deployed on a visible vessel to achieve vascular compression and can achieve homeostasis in up to 100% of cases.⁵⁵ Comparative studies suggest lower rebleeding rates than adrenaline injection,⁵⁶ ethanol⁵⁸ or saline/adrenaline injection.⁵⁸ The additional benefit of adrenaline with a mechanical method is unclear,⁵⁹ although one randomised comparative study of combination epinephrine-polidocanol injection and Hemoclip versus Hemoclip alone for bleeding peptic ulcers showed clipping to be inferior to combination therapy.⁶⁰ Two small studies have evaluated Hemoclips for control of bleeding due to Dieulafoy's lesion, demonstrating a trend towards reduction in the need for repeat procedures.^{61,62} Hemoclips can be technically difficult to apply if the ulcer is relatively inaccessible, for instance high on the gastric lesser curve or on the posterior duodenal wall. In fact, application of a clip with successful hemostasis in either of these locations has been as low as 30% in published series. Rotatable, versatile endoclip that can deploy multiple and stronger clips are needed.



Endoscopic band ligation (EBI) is currently technically easier to use than endoclips and has been shown to be safe and effective for control of small lesion in a small series of acute peptic ulcer⁶³ bleeding and with bleeding due to Dieulafoy's lesions.⁶⁴

Combined modalities

There is trend towards combined use of two endoscopic modalities using injection and mechanical or injection and thermal probe therapy in actively bleeding peptic ulcer. Adrenaline injection and thermocoagulation combined have shown lesser rebleed rates than injection alone in some studies whereas others have not been as conclusive. It is recommended by international and American Society of Gastro-Intestinal endoscopy (ASGE) guidelines also.^{65,66}

“Second-look” endoscopy and endoscopic re-treatment

The major challenge in applying endoscopic therapy for bleeding peptic ulcers is that hemostasis is not permanent and re-bleeding occurs in about 15-20% of the cases. Predictors of an increased risk of rebleeding and death (as well as failure of endoscopic therapy) include (i) clinical factors such as shock at the time of presentation, advanced age, co-existing illnesses, (ii) endoscopic features such as ulcer location (posterior duodenal ulcer), size of the ulcer > 2cm, stigmata of recent hemorrhage and the presence of blood at the time of endoscopy as well as (iii) laboratory features such as hemoglobin < 10 g/dl and elevated blood urea levels.⁶⁷⁻⁷⁰ Endoscopic treatment would avoid the surgical risk. However, delay in establishing hemostasis may result in hypotension and adversely affect the survival. In patients with peptic ulcers and recurrent bleeding after initial endoscopic control of bleeding, endoscopic retreatment reduces the need for surgery without increasing the risk of death and is associated with fewer complications than is surgery.⁷¹

Routine “second look” endoscopy, in the absence of established rebleeding or patient instability, has

gone out of vogue after studies showed no benefit with regards to clinically significant outcomes for unselected patient population,⁷² although there may be a role in high risk patients.⁷³⁻⁷⁴

Pharmacological Therapy

In vitro studies of the effect of gastric pH on platelet aggregation and coagulation provide the rationale for acid suppression in UGIB. If gastric pH is maintained above pH 6 (by infusional PPI), platelet aggregation is optimized and fibrinolysis relatively inhibited, thereby potentially improving the likelihood of clot stability at an ulcer site. Individual trials of H₂ receptor antagonists (H₂RA) have generally failed to demonstrate a clinical benefit in UGIB⁷⁵ although one meta-analysis has suggested a weak effect.⁷⁶ A recent consensus statement suggested that the available data on H₂RAs does not support their use in ulcer bleeding.⁷⁷

Several studies have evaluated intravenous proton pump inhibitors (PPI) for non-variceal UGIB; unfortunately, these trials are heterogeneous in terms of patient population, regimen of PPI and timing/type of endoscopic intervention, making comparisons difficult. However, meta-analysis of PPIs in non-variceal UGIB have now shown a benefit in terms of re-bleeding and need for surgery, but not for mortality.^{2,78-81} The usual intravenous regime for omeprazole therapy in the most robust studies was an 80 mg intravenous bolus of omeprazole followed by a continuous infusion of 8mg/hour for up to 72 hours. This regime resulted in a reduction of rebleeding from 22.5% to 6.7%.⁸⁰ Subsequent studies using lower intravenous doses of omeprazole or⁸² high dose oral omeprazole⁸³⁻⁸⁵ also demonstrated a reduction in rebleeding rate. Further study is required to determine the optimum dose, route of administration and dosing schedule of PPI in UGIB. In the meantime, and with the evidence currently available, it seems appropriate to treat patients with high risk peptic ulcers with intravenous or high dose oral PPI after endoscopic therapy has been administered.

ASGE guidelines recommended the use of PPI prior to endoscopy for patients with bleeding peptic ulcers or in those with suspected peptic ulcer bleeding in whom endoscopy is delayed or unavailable.⁶⁶ Oral PPI, even used at high dose, might not reliably sustain pH at a desired level of 6.⁸⁶ The usefulness of other pharmacological therapies such as somatostatin and its analogue octreotide is still a matter of debate.⁸⁷

Future Directions in Endoscopy

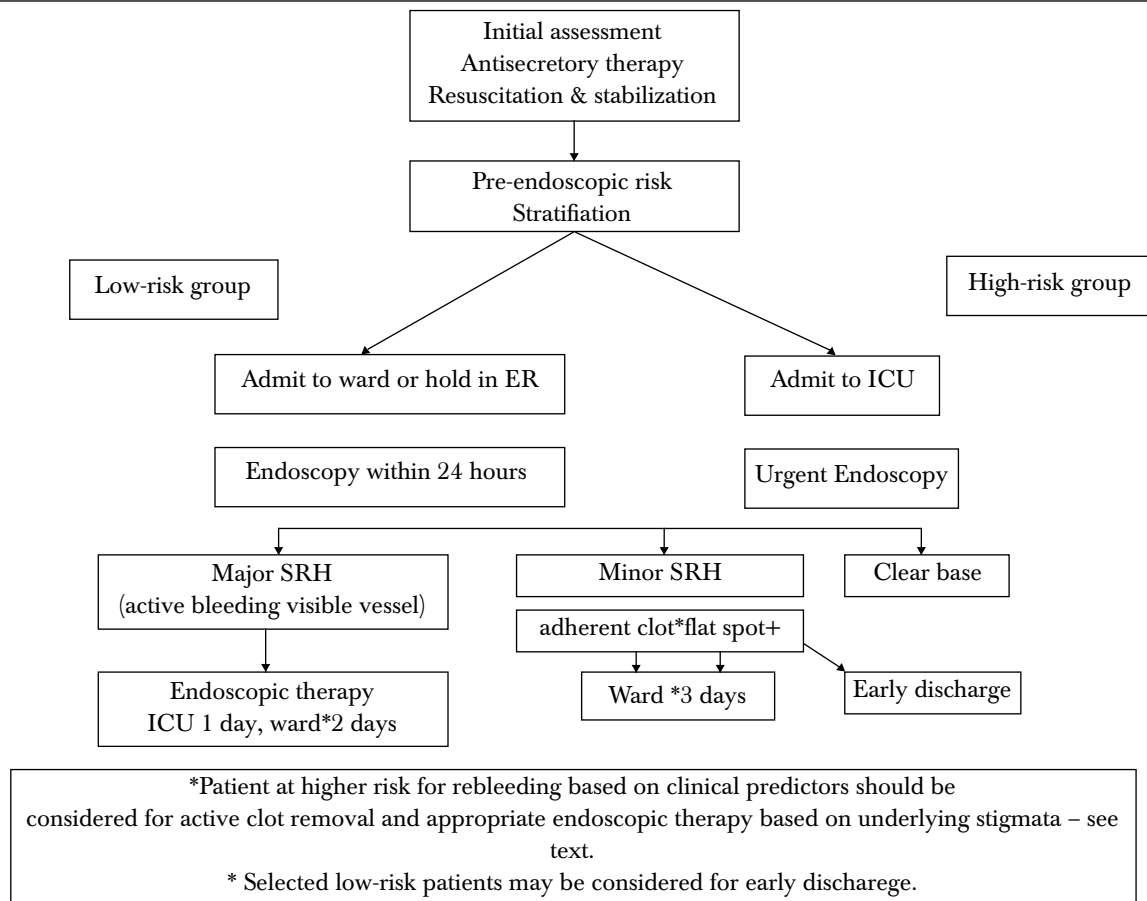
Currently available suturing devices are somewhat awkward to use and are not suitable for management of bleeding, although the principle of suturing peptic ulcers to control bleeding is well established in surgery. Further development is required before suturing becomes possible in the endoscopic sphere.

The risks associated with application of heat to bleeding lesions are due to the requirement for tissue contact, lack of control of depth of injury and difficulty in treating multiple or diffuse lesions. Gastric freezing to achieve hemostasis during variceal and non-variceal bleeding has been possible for several decades although evidence of therapeutic benefits from the original techniques was lacking and delivery systems were clumsy.⁸⁸ However, recent delivery of new liquid nitrogen or nitrous oxide delivery systems has made endoscopic cryotherapy feasible although still experimental.⁸⁹⁻⁹¹ Cryotherapy using nitrous oxide relies on the Joule-Thompson effect : rapid expansion of compressed gas results in a drop in temperature of the gas. The resultant “no contact” therapy has been tested in proctitis and may also be possible in upper gastrointestinal lesions.

Radiological approach

Angiography with transcatheter embolization provides a non-operative option for patients whose acute bleeding has not been identified or controlled by endoscopy.⁹² Recent studies support the safety and effectiveness of this approach for selected patients with acute non-variceal GI hemorrhage,⁹³⁻⁹⁴ given the appropriate expertise.

Treatment Algorithm For Acute Peptic Ulcer Hemorrhage



Surgery

Early consultation of surgical colleagues is part of a recommended multidisciplinary approach to patients with acute upper GI hemorrhage.⁹⁴ Epidemiologic studies have demonstrated that despite major advances in endoscopic treatment, the incidence of emergency surgery has not significantly changed.⁹⁵ Vagotomy and drainage procedures are technically simpler but are usually associated with higher ulcer recurrence rate much in contrast, vagotomy 2 resection approaches offer lower ulcer recurrences but represent more challenging operations and are associated with considerable morbidity and mortality.⁹⁶

Follow Up

Patients admitted for bleeding peptic ulcer should be discharged with oral proton pump inhibitors. Those with gastric ulcers should be re-endoscoped

in 6 weeks to assess healing and rule out malignancy. Attention should be paid to *Helicobacter pylori* eradication for all *H.pylori* positive ulcers. The latter is also recommended for those on long-term aspirin. Those who need to continue on NSAIDs should consider COX-2 inhibitors, or the least damaging NSAID with a proton pump inhibitor.

Consensus Recommendations for Endoscopic Management of Non-variceal upper GI bleed⁷⁷

- Early endoscopy (within the first 24 hours) with risks classification by clinical and endoscopic criteria allows for safe and prompt discharge of patients classified as low risk; improves outcomes for patients classified as either low or high risk.
- A finding of low-risk endoscopic stigmata is not an indication for endoscopic hemostatic therapy. A finding of a clot in an ulcer bed

warrants targeted irrigation in an attempt at dislodgement, with appropriate treatment of the underlying lesion.

- No single solution for endoscopic therapy is superior to another for hemostasis.
- No single method of thermal coaptive therapy is superior to another.
- Monotherapy with injection or thermal coagulation, is an effective endoscopic hemostatic technique for high risk stigmata; the combination is superior to either alone.
- The placement of clips is a promising endoscopic hemostatic therapy.
- Routine second look endoscopy is not recommended.
- In cases of rebleeding, a second attempt at endoscopic therapy is generally recommended.

Conclusion

Non-variceal UGIB is one of the most common emergencies that gastroenterologists encounter, and continues to be a significant cause of morbidity and mortality. The keys to management are rapid resuscitation and stabilization; appropriate triage based on pre-endoscopic risk factors; early endoscopy to achieve prompt diagnosis and implement hemostatic therapy to high-risk lesions; and aggressive antisecretory therapy (in the case of peptic ulcer bleeding) to reduce the risk of continued or recurrent bleeding.

References

1. Rockall TA, Logan RF, Devlin HB, Northfield TC. Incidence of and mortality from acute upper gastrointestinal hemorrhage in the United Kingdom. Steering Committee and members of the National Audit of Acute Upper Gastrointestinal Haemorrhage *BMJ* 1995 ; 311 (6999): 222-6.
2. Boonpongmanee S, Fleischer DE, Pezzullo JC, Collier K, Mayoral W, AL-Kawas F, et al . The frequency of peptic ulcer as a cause of upper- GI bleeding is Exaggerated. *Gastrointest Endosc* 2004; 59(7): 788-94.
3. Laine L, Peterson WL. Bleeding peptic ulcer. Time trends. *N Eng J Med* 1994;331:717-27.
4. Gabriel SE, Jaakkimainen L, Bombardier C. Risk for serious gastrointestinal complication related to use of nonsteroidal anti-inflammatory drugs: a meta analysis *Ann Intern med* 1991;115:787-96.
5. Godil A, Deguzman L, Schilling RC III, Khan SA, Chen YK. Recent nonsteroidal anti-inflammatory drug use increases the risk of early recurrence of bleeding in patients presenting with bleeding ulcer. *Gastrointest* 2000;146-51.
6. Laine L. Approaches to nonsteroidal anti-inflammatory drug use in the high-risk patient. *Gastroenterology* 2001;120:594-606.
7. Huang JQ, Sridhar S, Hunt RH . Role of Helicobacter pylori infection and non- steroidal anti-inflammatory drugs in peptic-ulcer disease: a meta-analysis. 2001;120:594-606.
8. Schiff L, Stevens R, Shapiro N, Goodman S. Observations on the oral administration citrated blood in man. II: The effect on the stools. *AM J Med Sci* 1942,203:409-12.
9. Daniel W, Egan S. The quantity of blood required to produce a tarry stool. *JAMA* 1939;15:131-4.
10. Wilcox CM, Alexander LN, Cotsonis G.A prospective characterization of upper Gastrointestinal hemorrhage presenting with hematochezia. *Am J Gastroenterol* 1997;92:231-5.
11. Silverstein FE, Gilbert DA, Tedesco FJ, Buenger NK, Persing J. The national ASGE survey on upper gastrointestinal bleeding. 11. clinical prognostic factors. *Gastrointest Endosc* 1981;27:80-93.
12. Provenzale D, Sndler RS, Wood DR, Levinson SL, Frakes JT, Sartor RB, et al. Development of a scoring system to predict mortality form upper gastrointestinal bleeding. *Am J Med Sci* 1987;294:26-32.
13. Rockall TA, Logan RF, Devlin HB, Northfield TC. Risk assessment after acute upper gastrointestinal hemorrhage. *Gut* 1996;38:316-21.
14. Corley D, Stefan A, Wolf M, Cook E, Lee T. Early indicators of prognosis in upper gastrointestinal hemorrhage. *Am J Gastroenterol* 1998;93:336-40.
15. Saeed Z, Ramirez F, Hepps K, Cole R, Graham D. Prospective validation of the Baylor bleeding score for predicting the likelihood of rebleeding after endoscopic hemostasis of peptic ulcers. *Gastrointest Endosc* 1995;41:561-5.
16. Hay J, Lyubashevsky E, Elashoff J, Maldonado L, Weingarten S, Ellrodt A. Upper gastrointestinal hemorrhage clinical guideline: determining the optimal hospital length of stay. *Am J Med* 1996;100:313-22.
17. Blatchford O, Murray WR, Blatchford M. A risk score to predict need for treatment for upper – gastrointestinal hemorrhage. *Lancet* 2003;356:1318-21.
18. Gilbert DA, Saunders D, Peoples J, Sillery J, Gulaseik C. Failure of iced saline lavage to suppress hemorrhage from experimental bleeding ulcers. *Gastroenterology* 1979;76:1138.
19. Gilbert DA, Saunders D. Iced saline lavage does not slow bleeding from experimental canine gastric ulcers. *Dig Dis Sci* 1981;26:1065-8.

20. Ponsky J, Hoffman M, Swayngim D. Saline irrigation in gastric hemorrhage: the effect of temperature. *J Surg Res* 1980;28:204-5.
21. Andrus C, Ponsky J. The effect of irrigant temperature in upper gastrointestinal hemorrhage. *Am J Gastroenterol* 1987;82:1062-4.
22. Rockall TA, Logan RF, Devin HB, Northfield TC. Selection of patients for early discharge or outpatient care after acute upper gastrointestinal hemorrhage. National Audit of Acute Upper Gastrointestinal Hemorrhage. *Lancet* 1996;347:1138-40.
23. Swain CP, Storey DW, Bown SG, Heath J, Mills TN, Salmon PR, et al. Nature of the bleeding vessel in recurrently bleeding gastric ulcers. *Gastroenterology* 1986;90:595-608.
24. Freeman ML, Cass OW, Peine CJ, Onstad GR. The non-bleeding visible vessel versus the sentinel clot: natural history and risk of rebleeding. *Gastrointest Endosc* 1993;39:359-66.
25. NIH Consensus Conference. Therapeutic endoscopy and bleeding ulcers. *JAMA* 1989;262:1369.
26. Laine L, Stein C, Sharma V. A prospective outcome study of patients with clot in an ulcer and the effect of irrigation. *Gastrointest Endosc* 1996;43:107-10.
27. Cook DJ, Guyatt GH, Salena BJ, Laine I. A meta-analysis of endoscopic therapy for acute non-variceal upper gastrointestinal hemorrhage: a meta-analysis. *Ann Intern Med* 1992;117:280-7.
28. Sacks HS, Chalmers TC, Blum AI, et al. Endoscopic hemostasis: an effective therapy for bleeding peptic ulcers. *JAMA* 1990;264:494-9.
29. Coffin B, Pocard M, Panis Y, Riche F, Laine MJ, Bitoun A, et al. Erythromycin improves the quality of EGD in patients with acute upper GI bleeding: a randomized controlled study. *Gastrointest Endosc* 2002;56(2): 174-9.
30. Frossard JL, Spahr L, Queneau PE, Giostral E, Burckhardt B, Ory G, et al. Erythromycin intravenous bolus in fusion in acute upper gastrointestinal bleeding: a randomized, controlled, double-blind trial. *Gastroenterology* 2002;123(1):17-23.
31. Rutgeerts P, Geboes K, Vantrappen G. Experimental studies of injection therapy for severe non-variceal bleeding in dogs. *Gastroenterology* 1989;97:610-21.
32. Rajgopal C, Lessels A, Palmer KR. Mechanism of action of injection of therapy for bleeding peptic ulcer. *Br J Surg* 1992;79:782-84.
33. Chung SCS, Leung JW, Steele RJ, et al. Endoscopic injection of adrenaline for actively bleeding ulcers: a randomized trial. *BMJ* 1988;296:1631-33.
34. Sung JY, Chung SC, Low JM, et al. Systemic absorption of epinephrine after endoscopic submucosal injection in patients with bleeding peptic ulcers. *Gastrointest Endosc* 1993;39:20-22.
35. Lin HJ, Perng CL, Lee FY, et al. Endoscopic injection for the arrest of peptic ulcer hemorrhage – final result of a prospective, randomized comparative trial. *Gastrointest Endosc* 1993;39:15.
36. Lai KH, Peng SN, Guo WS, et al. Endoscopic injection for the treatment of bleeding ulcers: local tamponade or drug effect. *Endoscopy* 1994;26:338.
37. Panes J, Viver J, Forne M, et al. Controlled trial of endoscopic sclerosis in bleeding peptic ulcers. *Lancet* 1987; ii:1292-94.
38. Rajgopal C, Palmer KR. Endoscopic injection sclerosis – effective treatment for bleeding peptic ulcer. *Gut* 1991; 32:727-29.
39. Oxner RBG, Simmonds NJ, Gertner DJ, et al. Controlled trial of endoscopic injection treatment for bleeding peptic ulcers with visible vessels. *Lancet* 1992;339:966-68.
40. Chung SCS, Leung JWC, Leong HT, et al. Adding a sclerosant to endoscopic epinephrine injection in actively bleeding ulcers – a randomized trial. *Gastrointest Endosc* 1993;39:611.
41. Villaneuva C, Balanzo J, Espinos JC, et al. Endoscopic injection therapy of bleeding ulcer – a prospective and randomized comparison of adrenaline alone or with polidocanol. *J Clin Gastroenterol* 1993; 17:195.
42. Choudari CP, Palmer KR. Endoscopic injection for bleeding peptic ulcer – a comparison of adrenaline alone with adrenaline plus ethanalamine oleate. *Gut* 1994;35:608.
43. Levy J, Khakoo S, Barton R, et al. Fatal injection sclerotherapy of a bleeding peptic ulcer. *Lancet* 1991;337:504 (Letter).
44. Luman W, Hudson N, Choudari CP, et al. Distal biliary stricture as a complication of sclerosant injection for bleeding duodenal ulcer. *Gut* 1994;35:1665-67.
45. Sugawa C, Fugita Y, Ikeda T, et al. Endoscopic hemostasis of bleeding of the upper gastrointestinal tract by local injection of ninety-eight per cent dehydrated ethanol. *Surg Gynecol Obstet* 1986;162:159-63.
46. Rutgeerts P, Gevers AM, Hiele M, et al. Endoscopic injection therapy to prevent rebleeding from peptic ulcers with a protruding vessel – a controlled comparative trial. *Gut* 1993;34:348.
47. Rutgeerts P, Rauws E, Wara P, Swain P, Hoos A, Solleder E, et al. Randomized trial of single and repeated fibrin glue compared with injection of polidocanol in treatment of bleeding peptic ulcer. *Lancet* 1997;350(9079):692-6.
48. Laine L. Multipolar electrocoagulation in the treatment of active upper gastrointestinal tract hemorrhage – a prospective controlled trial. *N Engl J Med* 1987;316:1613.
49. Laine L. Multipolar electrocoagulation in the treatment of peptic ulcers with nonbleeding visible vessels – a prospective, controlled trial. *Ann Intern Med* 1989;110:510.
50. Jaramillo JL, Carmona C, Galvez C, et al. Efficacy of the heater probe in peptic ulcer with a nonbleeding visible vessel – a controlled, randomized study. *Gut* 1993;34:1502.
51. Kanai M, Hamada A, Endo Y, Takeda Y, Yamakawa M, Nishikawa H, et al. Efficacy of argon plasma coagulation in nonvariceal upper gastrointestinal bleeding. *Endoscopy* 2004; 36(12): 1085-8.
52. Cipolletta L, Bianco MA, Rotondano G, Piscopo R, Prisco A, Garofano ML. Prospective comparison of argon plasma coagulator and heater probe in the endoscopic treatment

- of major peptic ulcer bleeding. *Gastrointest Endosc* 1998;48(2):191-5.
53. Probst A, Scheubel R, Wienbeck M. Treatment of watermelon stomach (GAVE syndrome) by means of endoscopic argon plasma coagulation (APC): long term outcome. *Zeitschrift for Gastroenterologic* 2001;39:447-52.
 54. Rutgeerts P, Vantrappen G, Broeckaert L, Coremans G, Janssens J, Hiele M. Comparison of endoscopic polidocanol injection and TAG laser therapy for bleeding peptic ulcers. *Lancet* 1989;1(8648):1164-7.
 55. Chou YC, Hsu PI, Lai KH, LoCC, Chan HH, Lin CP, et al. A prospective randomized trial of endoscopic hemoclip placement and distilled water injection for treatment of high-risk bleeding ulcers. *Gastrointest Endosc* 2003;57(3): 324-8.
 56. Nagasu N, DiPalma JA. Bleeding ulcer: inject or clip? *Am J Gastroenterol* 1998;93(10):1998.
 57. Nagayama K, Tazawa J, Sakai Y, Miyassaka Y, Yu SH, Sakuma I, et al. efficacy of endoscopic clipping for bleeding gastroduodenal ulcer: comparison with topical ethanol injection. *Am J Gasstroenterol* 1999;94(10):2897-901.
 58. Chung IK, Ham JS, Kim HS, Park SH, Lee MH, Kim SJ. Comparison of the hemostatic efficacy of the endoscopic hemoclip method with hypertonic saline-epinephrine injection and a combination of the two for the management of bleeding peptic ulcers. *Gastrointest Endosc* 1999;49(1):13-8.
 59. Buffoli F, Graffeo M, Nicosia F, Gentile C, Cesari P, Rolfi F, et al. Peptic ulcer bleeding: comparison of two hemostatic procedures. *Am J Gastroenterol* 2001; 96(1):89-94.
 60. Gevers AM, De Goede E, Simoens M, Hiele M, Rutgeerts P, A randomized trial comparing injection therapy with hemoclip and with injection combined with hemoclip for bleeding ulcers. *Gastrointest Endosc* 2002;55(4):466-9.
 61. Park CH, Sohn YH, Lee WS, Joo YE, Choi SK, Rew JS, et al. The usefulness of endoscopic hemoclipping for bleeding Dieulafoy lesions. *Endoscopy* 2003; 35(5):388-92.
 62. Yamaguchi Y, Yamato T, Katsumi N, Imao Y, Aoki K, Morita Y et al. Short-term and long-term benefits of endoscopic hemoclip application for Dieulafoy's lesion in the upper GI tract. *Gastrointest Endosc* 2003; 57(6):653-6.
 63. Park CH, Lee WS, Joo YE, Choi SK, Rew JS, Kim SJ. Endoscopic band ligation for control of acute peptic ulcer bleeding. *Endoscopy* 2004; 36(1):79-82.
 64. Mumtaz R, Shaukat M, Ramirez FC. Outcomes of endoscopic treatment of gastroduodenal Dieulafoy's lesion with rubber band ligation and thermal/injection therapy. *J Clin Gastroenterol* 2003;36(4):310-4.
 65. Barkun A, Bardou M, Marshall JK. Consensus recommendations for managing patients with non-variceal upper gastrointestinal bleeding. *Ann intern Med* 2003; 139:843-57.
 66. Adler DG, Leighton JA, Davila RE, Hirota WK, Jacobson BC, Qureshi WA, et al. ASGE guide-line: The role of endoscopy in acute non-variceal upper-GI hemorrhage. *Gastrointest Endosc* 2004; 60:297-504.
 67. Wong SK, Yu LM, Lau JYW et al. Prediction of therapeutic failure after adrenaline injection plus heater probe treatment in patients with bleeding peptic ulcer. *Gut* 2002; 50:322-5.
 68. Pundzius J. Clinical and endoscopic signs for the prediction of recurrent bleeding from gastroduodenal ulcers. *Eur J Surg* 1994;160:689-92.
 69. Thomopoulos et al. Factors associated with failure of endoscopic injection hemostasis in bleeding peptic ulcers. *Scand J Gastroenterol* 2001; 36:664-8.
 70. Hasselgren G et al. Risk for rebleeding and fatal outcome in elderly patients with acute peptic ulcer bleeding. *Eur J Gastroenterol Hepatol* 1998;10:667-72.
 71. Lau YW, Sung JY, Lam Y, Chan CW, Ng KW, Lee WH, Chan KL, Suen CY, Chung SC. Endoscopic retreatment compared with surgery in patients with recurrent bleeding after initial endoscopic control of bleeding ulcers. *N Engl J Med*. 1999;340:751-56.41
 72. Messmann H, Schaller P, Andus T, Lock G, Vogt W, Gross V, et al. effect of programmed endoscopic follow-up examinations on the rebleeding rate of gastric or duodenal peptic ulcers treated by injection therapy: a prospective, randomized controlled trial. *Endoscopy* 1998; 30(7):583-9.
 73. Villanueva C, Balanzo J, Torras X, Soriano G, Sainz S, Vilardell F. Value of second look endoscopy after injection therapy for bleeding peptic ulcer: a prospective and randomized trial. *Gastrointest Endosc* 1994; 40(1): 34-9.
 74. Saeed ZA, Second thoughts about second-look endoscopy for ulcer bleeding? *Endoscopy* 1998;30(7): 650-2.
 75. Walt RP, Cottrell J, Mann SG, Freemantle NP, Langman MJ. Continuous intravenous famotidine for hemorrhage from peptic ulcer. *Lancet* 1992; 340(8827): 1058-62.
 76. Collins R, Langman M. Treatment with histamine H2 antagonists in acute upper gastrointestinal hemorrhage. Implications of randomized trials. *N Engl J Med* 1985; 313(11): 660-6.
 77. Barkun A, Bardou M, Marshall JK. Consensus recommendations for managing patients with non-variceal upper gastrointestinal bleeding. *Ann Intern Med* 2003; 139(10):843-57.
 78. Selby NM, Kubba AK, Hawkey CJ. Acid suppression in peptic ulcer haemorrhage: a 'Meta-analysis'. *Aliment Pharmacol Ther* 2000;14(9):1119-26.
 79. Gisbert JP, Gonzalez L, Calvet X, Roque M, Gabriel R, Pajares JM. Proton pump inhibitors versus H2-antagonists: a meta-analysis of their efficacy in treating bleeding peptic ulcer. *Aliment Pharmacol Ther* 2001;15(7):917-26.
 80. Khuroo MS, Farahat KL, Kagevi IE. Treatment with proton pump inhibitors in acute non-variceal upper gastrointestinal bleeding: a meta-analysis. *J Gastroenterol Hepatol* 2005;20(1):11-25.
 81. Leontiadis GI, Sharma VK, Howden CW. Systematic review and meta-analysis of proton pump inhibitor therapy in peptic ulcer bleeding *BMJ* 2005; 330(7491):568.

82. Udd M, Miettinen P, Palmu A, Heikkinen M, Janatuinen E, Pasanen P, et al. Regular-dose versus high-dose omeprazole in peptic ulcer bleeding: a prospective randomized double-blind study. *Scand J Gastroenterol* 2001;36(12):1332-8.
83. Khuroo MS, Yattoo GN, Javid G, Khan BA, Shah AA, Gulzar GM, et al. A comparison of omeprazole and placebo for bleeding peptic ulcer. *N Engl J Med* 1997; 336(15): 1054-8.
84. Kaviani MJ, Hashgemi MR, Kazemifar AR, Roozitalab S, Mostaghni AA, Merat S, et al. Effect of oral omeprazole in reducing re-bleeding in bleeding peptic ulcers: a prospective, double-blind, randomized, clinical trial. *Aliment Pharmacol Ther* 2003; 17(2):211-06.
85. Javid G, Masoodi I, Zargar SA, Khan BA, Yattoo GN, Shah AH, et al. Omeprazole as adjuvant therapy to endoscopic combination injection sclerotherapy for treating bleeding peptic ulcer. *Am J Med* 2001; 111(4):280-4.
86. Pais SA, Nathwani RA, Dhar V, Nowain A, Laine L. Effect of frequent dosing of an oral proton pump inhibitor on intragastric pH. *Aliment Pharmacol Ther* 2006; 23:1607-13.
87. Arabi Y, Al knawy B, Barkun AN, Bardou M. Pro/con debate: octreotide has an important role in the treatment of gastrointestinal bleeding of unknown origin? *Crit Care* 2006; 10:218.
88. Wangenstein SI, Smith RB, Barker HG. Gastric cooling and gastric "freezing" *Surg Clin North Am* 1966; 46(2):463-75.
89. Pasricha PJ, Hill S, Wadwa KS, Gislason GT, Okolo PI, 3rd Magee CA, et al. Endoscopic cryotherapy: experimental results and first clinical use. *Gastrointest Endosc* 1999; 49(5):627-31.
90. Kantsevov SV, Cruz- Correa MR, Vaughn CA, Jagannath SB, Pasricha PJ, Kalloo AN. Endoscopic cryotherapy for the treatment of bleeding mucosal vascular lesions of the GI tract: a pilot study. *Gastrointest Endosc* 2003;57(3):403-6
91. Johnston CM, Schoenfeld LP, Mysore JV, Dubois A. Endoscopic spray cryotherapy: a new technique for mucosal ablation in the esophagus. *Gastrointest Endosc* 1999; 50(1):86-92.
92. Defreyne L, Vanlanagenhove P, De Vos N., Pattyn P, Van Maele G, Decruyenaere J. et al. Embolization as a first approach with endoscopically unmanageable acute nonvariceal gastrointestinal hemorrhage. *Radiology* 2001:218:739-48.
93. Rafique MZ, UL Haq Din GN, Ud Din MA, Chisty IA, Usman MU. Transcatheter embolization of acute non-variceal gastrointestinal hemorrhage. *J Coll Physicians Surg Pak* 2005; 15:81-4.
94. Park MH, Park GS, Park SW, Jhu LK, Jung PJ, Lee NH et al. Clinical effectiveness of transcatheter arterial embolization for acute upper and lower non variceal gastrointestinal bleeding. *Korean J Gastroenterol* 2005; 46:262-8.
95. Ohmann C, Imhof M, Roher HD. Trends in peptic ulcer bleeding and surgical treatment. *World J Surg* 2000;24:284-93.
96. de la Fuente SG, Khuri SF, Schiffner T, Henderson WG, Mantyh CR, Pappas TN. Comparative analysis of vagotomy and drainage versus vagotomy and resection procedures for bleeding peptic ulcer disease: results of 907 patients from the Department of Veterans Affairs National Surgical Quality Improvement Program database. *J Am Coll Surg* 2006; 202:78-86.