

CHAPTER

46

Polycythemia – How and How Much to Investigate?

P. K. Sasidharan

Introduction

Polycythemia is not uncommon, but often overlooked in the general examination, as we have not included polycythemia in the scheme, it is justified too because it is nothing compared to the vast ocean of anemias. Once it is detected then very few only know how to investigate and those who know the approach from the text books do not know often how much to investigate? Here is an attempt to answer these issues and to help those interested to adopt a practical and conservative approach suitable for our set up.

Definitions and causes

Polycythemia is a Greek word and it means too many RBCs, and conventionally it can be divided into true(real) and spurious(apparent), only in the former there is true increase in number of RBCs. True polycythemia thus means there is an increase in red cell mass, apparent or spurious polycythemia occurs when there is an acute reduction in plasma volume following severe dehydration as happens in diarrhea, vomiting, use of diuretics, capillary leak syndromes and in severe burns. Sometimes spurious polycythemia is due to improper interpretation of a normal Hb that is in the upper limit of normal.

When true polycythemia occurs by a mechanism independent of erythropoietin (EPO) with

normal erythropoietin levels we call it as primary polycythemia. The erythroid progenitors in the bone marrow respond in an exaggerated manner to normally secreted erythropoietin, or even independent of EPO in the primary polycythemia, the prototype of which is polycythemia rubra vera (PRV). This is considered as one of the myeloproliferative disorders. A rare type of primary polycythemia can occur as a hereditary form called as primary familial and congenital polycythemia (PFCP), in which the disorder is an intrinsic problem with erythropoiesis.

True polycythemia can also be produced by increased erythropoietin levels which is called as secondary polycythemia. The increased EPO secretion is in response to a physiological stimulus, like hypoxia, or it can be that EPO is pathologically secreted from kidneys or elsewhere. In normal adult males a hemoglobin of more than 17 g/dL or a PCV more than 50 per cent can be taken as abnormal. In females the corresponding values are Hb 15 g/dL and a PCV of 45%. There are some exceptions occasionally but where the PCV is more than 60% in men and more than 55% in women it almost invariably means increased red cell mass or true polycythemia.

True polycythemia can also be divided into congenital or acquired.

Congenital causes of True Polycythemia

1. *Familial and Congenital Polycythemia*
2. *Chuvash Polycythemia.*
3. *Mutant Hb with high affinity*
4. *2,3 DPG deficiency*

Familial and Congenital Polycythemia

Normal Leukocyte and platelet counts, hyper responsiveness of erythroid progenitors to EPO, low erythropoietin level, normal oxygen affinity of Hb, absence of progression to Leukemias and autosomal Dominant inheritance.

Chuvash Polycythemia

The commonest type of congenital Polycythemia was first described in Russia. A defect in oxygen sensing leads to increased erythrocytosis even with normally secreted erythropoietin (primary polycythemia). This is a disorder affecting hundreds to thousands in an ethnic minority in Russia but is present in other parts of the world as well.

Mutant Hb with high affinity

Mutations of alpha or beta globulin gene can cause it, more than 50 variants are identified; Autosomal Dominant inheritance and resultant high affinity for Hb and decreased oxygen delivery to tissues leads to erythropoietin mediated increase in hemoglobin. But by definition the polycythemia here is secondary, though it is congenital.

2,3 DPG deficiency

Due to firm binding of oxygen to hemoglobin there is a defective oxygen unloading in the tissues which leads to hypoxia and increased erythropoietin secretion and consequent increase in erythrocytosis (secondary polycythemia). It Can be autosomal dominant or autosomal recessive.

Diagnosis of these congenital disorders is possible only by family history, exclusion of acquired disorders and finally determination of oxygen dissociation kinetics, looking for the mutant Hb and if there is no mutations then biochemical assay for 2,3 DPG from freshly obtained RBCs. The

latter investigations are required only for research purposes and not on a routine basis in the work up.

Causes of secondary Polycythemia

(EPO dependent - can be congenital also)

EPO mediated-hypoxia driven

- Chronic lung Diseases
- Chronic Carbon monoxide exposure (smoking)
- Right to Left Cardiac shunts
- High Altitude
- Hypoventilation syndromes
- Sleep apneas
- Respiratory center dysfunctions
- Renal artery stenosis
- High affinity Hb (Autosomal Dom)
- 2, 3 DPG deficiency

Pathologic EPO production***Malignant tumors producing excessive erythropoietin***

- *Hepatocellular carcinoma*
- *Renal cell Cancer*
- *Cerebellar hemangioblastoma*

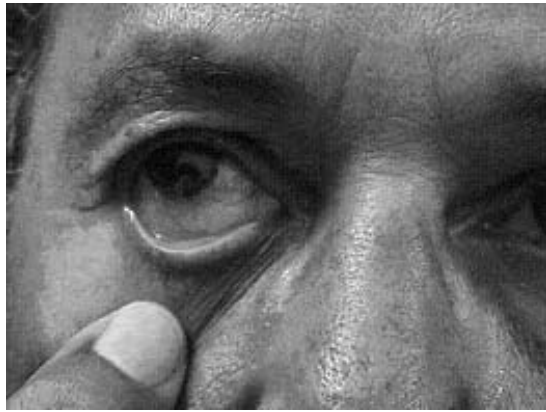
Non malignant conditions

- *Uterine leiomyoma*
- *Renal cysts*
- *Hydronephrosis*
- *Adrenal tumors*
- *Atrial myxoma*
- *Post-renal transplantation*

Miscellaneous causes

- *Androgen abuse*
- *EPO abuse*
- *Familial polycythemia(AD)*
- *Chuvash Polycythemia*

Figure 1 : Ruddy complexion and the conjunctival congestion in an Indian Patient with Polycythemia Rubra Vera



Clinical approach to True polycythemia

Clinical presentations

Very often patients with polycythemia are asymptomatic or have only vague complaints like heaviness of head. Viscosity of blood increases disproportionately at hematocrits more than 55% and hence symptoms due to high red cell mass can be there, these are mostly due to thrombotic events (both venous and arterial) and diminished blood flow manifesting as-

- Digital ischemia
- Budd-Chiari syndrome
- Vertigo, tinnitus, headache, and visual disturbances.

Hypertension and polycythemia together can be seen in Polycythemia Rubra Vera, Renal artery stenosis, Polycystic kidney diseases and sometimes in other renal diseases with increase in renin and erythropoietin. In one of the patients with hypertension, whom the author had seen it was nephrocalcinosis due to hyperparathyroidism which was the cause of polycythemia(see below). Easy bruising, epistaxis, or GI bleeding can occur in PRV, in addition to other problems of polycythemia, probably due to the coexisting platelet dysfunction. The chronic hypoxemia can manifest as headache, impaired mental acuity, fatigue and cyanosis on

minimal exertion. *Polycythemia causes increased blood viscosity and thus raises pulmonary artery pressure; Hypoxemia also increases pulmonary vascular resistance and the combination of these two as happens in chronic lung disease can often lead to cor pulmonale.*

While examining patients, always look for clinical features of polycythemia as suggested by congestion of eyes, palmar erythema and a ruddy complexion which is very obvious in the relatively fair-skinned, but can be overlooked in those with dark skin. Very often anemia alone is looked for and not for evidence of Polycythemia. Confirm its presence by Hb, and PCV from a reliable laboratory. Very low ESR (< 10 mm) and a high hemoglobin is an important clue to the presence of Polycythemia. If any doubt exists we should get a repeat estimation of Hb and PCV from a reliable place.

Having detected and confirmed the presence of polycythemia, awareness about all the causes of polycythemia and their clinical features is absolutely essential to differentiate between the causes. Using the clinical skill look for secondary causes of polycythemia by history, physical examination and Hemogram, similarly look also for features of PRV.

Historical features to find out the etiology

Get details of smoking, especially chronic heavy smoking; look for symptoms of congenital heart disease, sleep-apnea, chronic lung disease, renal disease, history of living at high altitude; symptoms of peptic ulcer disease, and aquagenic pruritus- as in PRV, and any family history as in rare congenital polycythemias.

Physical Examination

Always look for findings suggestive of polycythemia like the congested eyes, plethoric face and ruddy complexion. Features of secondary causes attributable to the diseases mentioned before like evidence of a right-to-left shunt (TOF, PAH) or of chronic lung disease, renal lumps or bruit should be looked for. Splenomegaly favors primary polycythemia especially when there are no other

secondary causes on simple clinical evaluation, but splenomegaly may not be seen early in the course of PRV.

Clinical Features of Polycythemia Rubra Vera (PRV)

Features that support the diagnosis of PRV

- Acquired polycythemia of late onset and no family history
- Absence of features of secondary causes
- Aquagenic pruritus
- Symptoms related to hepatosplenomegaly
- Polycythemia without any known secondary cause
- Splenomegaly on examination
- Elevated Total Leukocyte count,
- Increased basophil count
- Thrombocytosis,
- Elevated uric acid
- Elevated Leukocyte Alkaline Phosphatase
- Elevated serum vitamin B₁₂ and vitamin B₁₂-binding protein levels.

The last two are almost never done to diagnose PRV, leave alone the JAK 2 mutation analysis. In case there is any diagnostic confusion follow up the patient regularly with periodic venesection – a period of observation and review will settle the doubt in remaining cases.

Polycythemia Vera, diagnostic criteria

- Elevated red cell mass
- Normal arterial oxygen saturation
- Splenomegaly, -- or *if splenomegaly is absent Leukocytosis and thrombocytosis*
- *No other cause for polycythemia*

Applying clinical skills alone one can arrive at the diagnosis in almost all cases of polycythemia. If at all occasionally one has to do some investigations, it is to rule out certain secondary causes, like X-ray Chest, USG abdomen or rarely

Echocardiography. If none is obvious a period of observation with venesection will settle the issue rather than resorting to all costly investigations. So far we never had to resort to erythropoietin levels to differentiate between primary and secondary polycythemia. Clinical evaluation itself has given the clue to the cause in majority, hemogram has settled the confusion in the remaining patients, and to study the problem better or to exclude a renal and cardiac cause we had done USG abdomen and echo cardiograph in a handful of cases.

Steps in Clinical Approach (practical guidelines) :

- Exclude spurious/apparent polycythemia by history and clinical setting.
- Exclude secondary causes based on clinical features and simple laboratory tests.
- Look for clinical and laboratory features of primary polycythemia as described already.
- Consider the rare familial forms - if in case there is a family history as well, do not depend on EPO levels.
- If still in doubt keep the patient under follow up with lifestyle modification like quitting smoking and adopting other healthy lifestyle habits and venesection to reduce the PCV.
- Keep the patient under regular follow up, the actual picture will emerge during follow up.

Steps in Evaluation- as given in popular text books

- Assess red cell mass - ⁵¹Cr-labeled autologous red blood cells infused into the patient and sampling blood radioactivity over a 2-h period.
- If the red cell mass is normal (36 mL/kg in men, 32 mL/kg in women), the patient has spurious polycythemia.
- If the red cell mass is increased, serum EPO levels should be measured.

- If EPO levels are low or absent, the patient most likely has polycythemia vera.
- If EPO levels are elevated follow the steps given below to differentiate between-
 - a. *physiologic response to hypoxia and*
 - b. *related to autonomous production*
 - *Do arterial O₂ saturation (if less than 92%) - evaluate for heart or lung disease*
 - *If normal O₂ saturation in smokers + elevated EPO levels could be because of Carbon monoxide displacement of O₂*
 - *If carboxy hemoglobin (COHb) levels are high in them -diagnosis is smoker's polycythemia*
 - *High affinity Hb;evaluated by elevated O₂-hemoglobin affinity*
 - *Consider ectopic EPO production that is not responding to the normal feedback inhibition*

EPO-producing lesions- look for them

Hepatoma, uterine leiomyoma, and renal diseases or cysts, Cerebellar Hemangiomas, atrial myxoma.

Apparently the approach is very simple and straightforward, but is not possible to be practiced even in the best of centres and it depends entirely on laboratory values leaving aside more important clinical pointers which spoils the more essential clinical skill as well.

Do we always need such an approach ??? .Is not proper clinical evaluation enough??

Yes we can have an alternative approach with very little cost and no suffering for the patient if we improve clinical acumen and use of common sense.

But one should know the common causes and their clinical features and should be using them supplemented by carefully selected, easily available, laboratory tests to apply this skill properly.

Polycythemia vera

It is a chronic myeloproliferative disorder, some cases have to be differentiated from other myeloproliferative disorders like idiopathic myelofibrosis, essential thrombocytosis, and chronic myeloid leukemia (CML), since polycythemia can sometimes occur in these disorders also, though it is uncommon. This differentiation becomes important at times when polycythemia could be masked by sequestration of RBCs in a hugely enlarged spleen and also because myelofibrosis can occur along with PRV as well. It is a clonal disorder involving a multipotent hematopoietic progenitor cell. We get phenotypically normal RBCs, granulocytes and platelets and there is no recognizable physiologic stimulus for erythrocytosis. It is not common in children, Leukocyte Alkaline Phosphatase(LAP) is increased in many and elevated serum vitamin B₁₂ or B₁₂-binding capacity may be present. Acid-peptic disease, occult gastrointestinal bleeding may even lead to presentation with hypochromic, microcytic blood picture with relatively preserved Hb level and the diagnosis could be missed.

Points to remember while evaluating a suspected Polycythemia Vera?

- We can miss polycythemia in PRV: Plasma volume is frequently elevated in PRV and it can mask the true extent of red cell mass or even its presence. In the presence of very large spleen all the red cells may be pooled in it and patients can have a PCV within the normal range. Therefore if we get a normal PCV with moderate or massive splenomegaly one should suspect PRV.
- Hepatic or portal vein thrombosis in patients with undefined myeloproliferative disorder could be Polycythemia Rubra Vera.
- Hemoglobin or hematocrit level is affected by the plasma volume. Hematocrit and red cell mass are not often linearly related, and red cell mass determination with radioisotope studies may be resorted to in a difficult case to distinguish absolute erythrocytosis from relative

erythrocytosis. It is also said to be required in rare situations in a suspected polycythemia Rubra Vera with normal hemoglobin with massive splenomegaly or for research purposes. But red cell mass determination is practically never required in the hands of good clinicians, and we need that approach in the Indian context.

- There are no clonal markers or specific cytogenetic abnormality for PRV and bone marrow aspirate and biopsy are not needed for the diagnosis. Bone marrow study is rarely done, if at all, only to establish the presence of myelofibrosis/ to exclude some other disorder. JAK 2 mutation analysis is being used now a days but its cost effectiveness and usefulness is not established and is only a research tool as on today. Occasionally Trisomy 8 or 9 or 20q- in the setting of an expansion of the red cell mass supports the clonal etiology but absence of a cytogenetic marker does not exclude the diagnosis of PRV.
- All said and done in some patients, only with time, the underlying PRV becomes apparent but the diagnostic ambiguity does not prevent initiation of therapy with venesection. And the overall quality of life and quantity of life is not altered by the aggressive investigative approach to diagnosis.

Management guideline for PRV in our set up

- Detect polycythemia clinically
- Confirm it, if necessary by a repeat PCV
- Look for secondary causes
- Look for features of PRV
- Venesection
- Follow up
- Re-evaluation periodically
- Can be managed without costly investigations

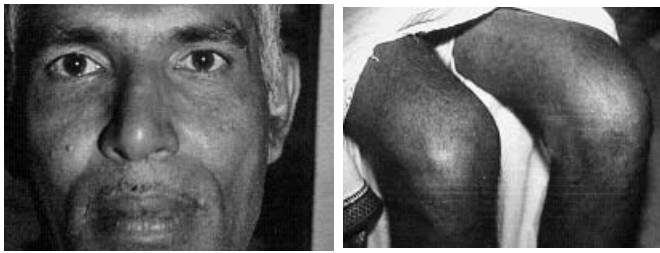
Case histories to highlight the value of good clinical evaluation

1. 17 year old plus two students who were asymptomatic before, recently noted breathlessness while playing. He was asymptomatic till six months ago and had no cardiovascular or respiratory disease in the past. The doctor whom he consulted detected congestion of the eyes and genuinely suspected polycythemia. Hb was 16.8, PCV was 48. All investigations for polycythemia including erythropoietin levels were done and there was no cause and was advised venesection. At this stage a doctor-relative of the patient referred him for a second opinion. On reviewing the history, though there was no cough or wheeze, he had history of allergic rhinitis. His physical examination was unremarkable but for the congestion of eyes. The cause of his symptom was obviously due to mild bronchospasm and increased work of breathing, which was obvious from the atopic tendency that he had. Instead of reviewing the history and physical examination and probably rechecking the Hemogram and PCV he was subjected to a series of investigations including USG, echo, serum erythropoietin and Hb electrophoresis and finally arrived at a diagnosis that he does not have- the fate of some patients these days is classically represented in this case history.

Investigations already done elsewhere in the patient as per textbook guidelines; Hb 16.8 gm%, PCV 48 ml/dl, TC: 5800/cmm, DLC :P 54% L 38% E 5% M 3%, Chest X-ray, Normal, ECG normal, ECHO and USG of abdomen Normal, Hb Electrophoresis Normal, LAP score: 35(35-100), Vit B12 assay- 399 (Normal 211-911), EPO level: 16.6 U/L (Normal 0.25 – 27.7 U/L)

On review of history in our institution– it was noted that the boy had changed over to a residential school six months prior to that, he stopped playing, took excess non vegetarian food and excess calories and put on weight, in addition he had atopic tendency with allergic rhinitis which were enough

Figures 2 and 3 : Ruddy complexion and effusion in R knee due to gouty arthritis in PRV



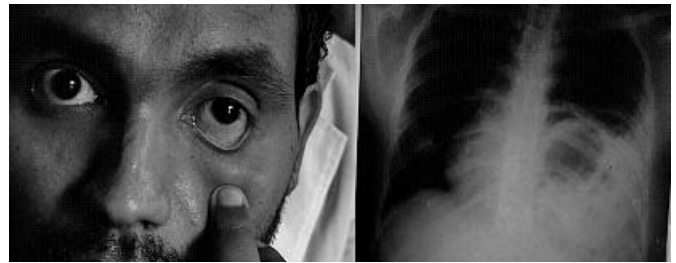to explain his symptom of breathlessness when he attempted at playing again. His weight gain and a sub clinical, exercise-induced bronchospasm was considered as the causes for his symptoms. Proper physical examination revealed no secondary cause for polycythemia, and the congestion of eyes he had was related to his atopic tendency. Repeat Hemogram in the patient showed Hb 15.7 gm%, TC 5800/cmm, P 55%, L 34%, E 11%, ESR 20 mm at the end of 1 hour, PCV 46.5 ml/dl and a Platelet count of 2.7 Lakh/cmm. Even the possibility of polycythemia was ruled out on clinical evaluation alone. The treatment given were Cetirizine + Deriphylline + Diet change to restrict calories and on follow up he was asymptomatic

Conclusion: Atypical asthma, recent weight gain + increased work of breathing Hb and PCV in the upper limit of normal, no polycythemia

Case history 2 : Patient with misdiagnosed PRV

50 Male nonsmoker – referred for arthritis with effusion in knees and ankles, while he was on ATT for a hemorrhagic pleural effusion. Since he was getting pyrazinamide we suspected gouty arthritis and the serum uric acid was found to be 11 mg/dL. In addition he had a plethoric face but the PCV initially was normal from one lab and the diagnosis was overlooked even when he had a ruddy complexion suggestive of polycythemia. To confuse one further splenomegaly was absent at that point of time, on review a repeat PCV was 59 ml/dl, and he was given one venesection with a possible diagnosis of PRV. We could conclude that the pleural effusion was actually due to pulmonary thromboembolism and pulmonary infarct as he had no fever, weight loss or raised ESR then. There were

Figures 4 and 5 : Ruddy complexion and the eventration of diaphragm on left side



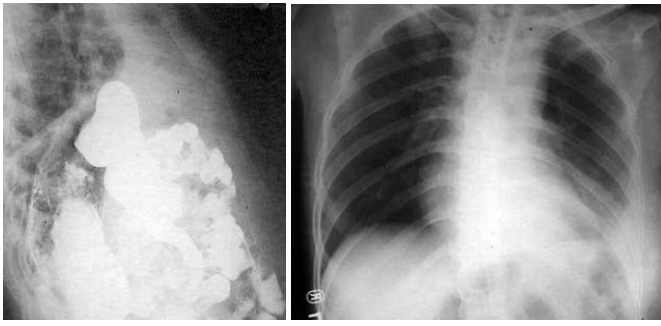
no obvious secondary causes for Polycythemia, and the hemogram was normal even then the possibility of PRV was kept with plans for regular venesection, but he was lost to follow up. One year later he developed acute myocardial infarction and was advised angiography by the treating cardiologist who missed the contribution by polycythemia to his problems. At this point he came for review to get a second opinion before angiography, this time splenomegaly was detected and the PCV was 62 ml/dl, TLC was 16000/cmm with occasional basophils in peripheral smear, and the diagnosis of PRV was confirmed and venesections were repeated. Since then he is on regular follow up and is on hydroxyurea as well. The Myocardial Infarction was actually due to polycythemia and the hypercoagulability in addition to possible coronary artery disease.

Case history 3: Diagnosed as PRV but actually secondary polycythemia

25 year old male, with polycythemia, had three episodes of stroke in the last 5 years with residual hemiplegia, diagnosed PRV from a peripheral hospital and was on venesection and Hydroxyurea for the last five years. Recently he was admitted in Calicut Medical College hospital with two days history of high fever and acute onset severe breathlessness following a lower respiratory infection. Review of his X-rays and barium studies he already had with him confirmed the diagnosis of eventration of diaphragm on the left side.

We realised that the surgery for eventration was previously deferred due to the problem of polycythemia. This time he was very sick with respiratory distress and was given venesections to

Figures 6 and 7 : Showing the eventration of diaphragm, and the CXR after repair of the eventration



lower the hematocrit followed by low dose heparin and antibiotic and when he improved an emergency surgery was done with informed consent. He improved remarkably after the surgery and is under follow up.

In fact it was not polycythemia rubra vera, just by a review of his clinical features like his age of onset and the total duration of the disease, absence of splenomegaly, normal total leukocyte and platelet counts, normal uric acid, and absence of basophils in peripheral blood, and a low oxygen saturation. The cause of chronic hypoxia was the eventration of diaphragm. If at all, there could be an element of hyperresponsiveness of erythroid progenitors to mild hypoxia and not PRV anyway.

The diagnosis in this case was chronic hypoxia due to eventration with secondary polycythemia and was not Polycythemia rubra Vera.

Case history 4: An unusual Right to left shunt causing polycythemia

25 year old female was admitted in a critical state, had severe CCF, cyanosis, polycythemia and very high JVP; her husband even wanted to take her home considering the seriousness of her illness, stayed back only because we insisted. She was previously worked up at many major centers inside and outside Kerala, and the diagnosis was confirmed as primary pulmonary hypertension and right to left shunt through patent foramen ovale. Only on our request they stayed back to see whether something could be done: On evaluation polycythemia and

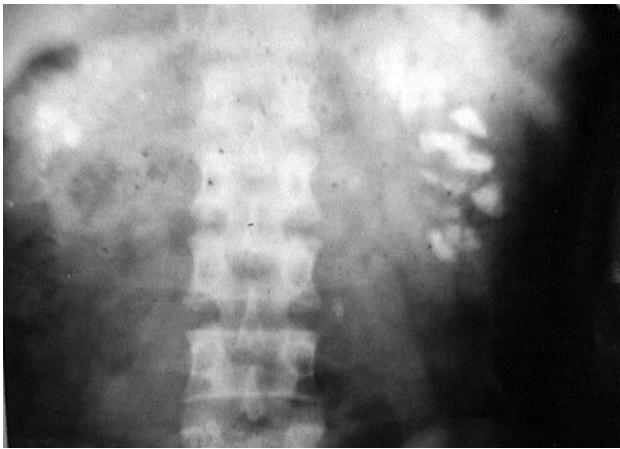cyanosis were obvious, the PCV was 68 ml/dl, she was given, Heparin + Venesection and decongestive therapy and showed some improvement. Review of history then revealed repeated abortions, polyarthralgia, but Antiphospholipid antibody was negative, ANA negative, AntiDsDNA negative. Even then the clinical setting was highly suggestive of Antiphospholipid antibody syndrome (APLA) probably SLE or primary APLA. It was obvious that everyone was carried away by the laboratory results alone ignoring the age, gender, clinical features etc. A clinical diagnosis of recurrent pulmonary embolism presenting as primary pulmonary hypertension was made and we were almost certain of this diagnosis even with her normal investigations. But in fact the investigations which were ignored as normal were all borderline, with a strong clinical diagnosis they were as good as positive.

She was started on steroid and immunosuppressants with informed consent considering this clinical diagnosis, anyway we had nothing to lose. She improved and had lived happily for another three years, but died due to another bout of severe congestive cardiac failure precipitated by a respiratory infection. What is highlighted by the case is that investigations may not always help us to confirm the diagnosis, we need to have a good clinical judgment, of course investigations are also looked at in formulating this judgment.

Case history 5: Polycythemia due to Nephrocalcinosis

25 year male non smoker was working in Saudi Arabia, came with giddiness, he was not aware of hypertension in the past, his BP was 200/130 mm Hg, eyes were congested, his PCV was 64 ml/dl, clinically and with investigations there was no respiratory or cardiac cause for the polycythemia, and there was no features to suggest PRV. He was given venesection, and anti hypertensives. During the evaluation for polycythemia an USG showed Nephrocalcinosis, confirmed by plain X-ray abdomen. Serum Ca was 12.6 mg%, Phosphate 2 mg%, uric acid 8 mg%, normal alkaline phosphatase, RFT was normal. PTH was elevated – The diagnosis

Figure 8 : Nephrocalcinosis which was causing polycythemia- case 5

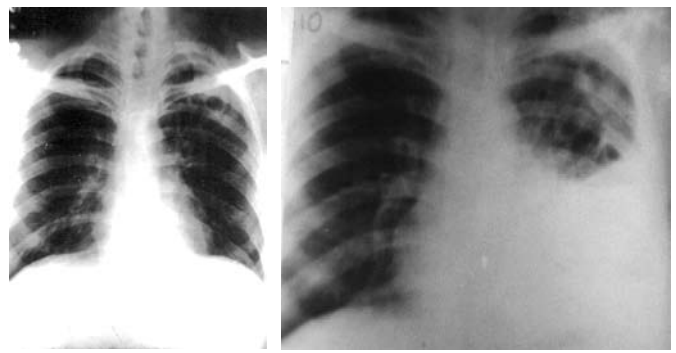


in this patient was Hyperparathyroidism with HTN and Nephrocalcinosis which was the only possible cause for his polycythemia. Nephrocalcinosis is not described as a cause for polycythemia, but several other renal diseases capable of irritating the renal interstitium is known to have polycythemia, like polycystic kidney disease, hydronephrosis etc then why not nephrocalcinosis? He was not willing for surgery as he had to go back to gulf urgently and was lost to follow up. Clinically and with all possible investigations he had no other cause of polycythemia.

Case 6 : Smoker's polycythemia with pulmonary thromboembolism with infarct and hemorrhagic effusion

25 Male, chronic heavy smoker, developed left shoulder pain while he was traveling by standing in a bus and carrying a stereo music system weighing some 5 kg in his left hand, his physical examination was rather unremarkable. Initially it was considered as musculoskeletal pain and was given analgesics and local heat. There was no relief and he came back the next day, this time he had left sided pleuritic chest pain as well and it was noticed that he had congestion of eyes and there was mild yellowish tinge to the eyes; but his wife said his eyes had that yellowish tinge always. There was unconjugated hyperbilirubinemia on investigation. Once polycythemia was confirmed (PCV was 64 ml/dl) the possibility of pulmonary infarction

Case 6 : LUZ lesion and the hemorrhagic effusion



as the cause of his left sided chest pain also was considered. The CXR was done, which showed a left upper zone shadow which was supposed to be due to tuberculosis which he had one year ago. In fact Tuberculosis was diagnosed when he presented with hemoptysis last year, but the history then was that he did not have any fever or weight loss, only hemoptysis and he was put on ATT with the chest x-ray findings in the left upper zone. Now in this background even that appeared to be a pulmonary infarct with hemoptysis. Clinically polycythemia and pulmonary infarct was certain in this patient due to the axillary vein thrombus which developed while traveling by bus with immobilized folded hands because he was carrying a weight; minor trauma due to the hard object he carried tucked to the axilla and due to the fact he was standing might have contributed to some endothelial damage as well, completing the Virchow's triad of stasis, hypercoagulability and endothelial injury. He was started on heparin, and venesection was given and was being worked up for the cause of polycythemia. There was no obvious cause detected clinically or by USG abdomen, while doing USG the sonologist noticed that there was mild left sided pleural effusion which was not present at admission, and it was a large pleural effusion by the time CXR was arranged, it was a hemorrhagic effusion as expected in this setting.

During the work up we also had a doubt about possible right atrial myxoma as the cause for polycythemia and the pulmonary embolism, and an echocardiography was asked for. The doctor who did the echo study diagnosed biatrial myxoma and

advised immediate surgery for which there was no facility at that time in the hospital where the patient was admitted and he had to be referred to another hospital some 300 km away. I saw this patient in 1992 when I happened to work in a private hospital for a short period. They were asked to bring 10 donors as well for emergency surgery from the referral center. After reaching the referral center just by reviewing the clinical features and the echo films they said it was simply an artifact due to coexisting large pleural effusion; however they repeated the study and concluded that there was no atrial myxoma and the patient was sent back. We aspirated the effusion; which was hemorrhagic due to heparin administration, which substituted the purpose of venesection as well, while still continuing heparin at a reduced dose, slowly it settled down and there was some residual effusion which was left alone. It was not possible to introduce chest tube in this patient while on anticoagulation and we had to aspirate the hemorrhagic effusion four times. Author has the follow up of this patient for the last 15 years by now. He does not smoke or take non vegetarian food now and does not have any polycythemia, and no icterus confirming that what he had was smoker's polycythemia and the jaundice was due to the pulmonary infarct.

This case history clearly elicits the importance of good clinical evaluation for accurate diagnosis and the disadvantages and suffering to patient and relatives by overdependence on investigations. Investigative Medicine is all out spoiling clinical

medicine and clinicians, and patients all over the world pay a heavy price for it. Something urgently has to be done to glorify clinical medicine and clinical skills to bring back the rapidly losing acceptance and glory of Modern Medicine.

References

1. Robert T Means, JR, Erythrocytosis, Wintrobe's Clinical Hematology Williams & Wilkins, 10th edition Chapter 59, Vol 2:1538-1554
2. Robert T Means, JR, Polycythemia Vera, Wintrobe's Clinical Hematology Williams & Wilkins, 10th edition Chapter 91, Vol 2:2374-2389
3. Joseph T Prchal, Earnest Beutler, Primary and Secondary Polycythemia, Williams hematology, seventh Edition, McGraw- Hill, Chapter 56: 779-802
4. Jerry L Spivak, Polycythemia Vera and other Myeloproliferative diseases, Harrison's Principles of Internal medicine, McGraw-Hill, 14th edition Vol 1, Chapter 111: 679- 684
5. Eugene Braunwald, "Hypoxia Polycythemia and Cyanosis" Harrison's Principles of Internal medicine, McGraw-Hill, 14th edition Vol 1, Chapter 36: 205-209
6. Joseph T Prchal, Xylina Gregg, "Hemoglobinopathies, Methemoglobinemias, Polycythemia and unstable hemoglobins" Cecil Textbook of Medicine, Saunders, 22nd edition, Vol I Chapter 172, 1039-1042
7. Ayalew Tefferi, "Polycythemia and related disorders" Cecil Textbook of Medicine, Saunders, 22nd edition, Vol I Chapter 176 ; 1057-1060
8. DJ Weatherall "Polycythemia Vera" Concise Oxford Textbook of Medicine, Oxford University press, First edition, Chapter 3.9; 201-204
9. DJ Weatherall "Relative and secondary polycythemia" Concise Oxford Textbook of Medicine, Oxford University press, First edition, Chapter 3.26; 261-263