

The rise in the spread of Zika virus has been accompanied by a rise in cases of microcephaly and Guillain-Barré syndrome. In 1947, A STUDY OF YELLOW FEVER YIELDED THE FIRST ISOLATION OF A NEW virus, from the blood of a sentinel rhesus macaque that has been placed in the Zika Forest of Uganda. Zika virus remained in relative obscurity for nearly 70 years; then, within the span of just 1 year, Zika virus was introduced in to Brazil from the Pacific Islands and spread rapidly throughout the Americas. It became the first major infectious disease linked to human birth defects to be discovered in more than half a century and created such global alarm that the World Health Organization (WHO) would declare a Public Health Emergency of International Concern.

THE HISTORY OF ZIKA VIRUS

Zika virus is flavivirus, in the family Flaviviridae. In 1947 scientists identify a new virus in a rhesus monkey in the Zika forest of Uganda - named as the Zika virus. In 1948 the virus is then recovered from the mosquito *Aedes africanus*, caught in the Zika forest. In 1952 the first human cases of Zika are detected in Uganda and the United Republic of Tanzania. In 1964 a researcher in Uganda is infected with Zika while working on the virus confirming that Zika virus causes human disease. In 1960s - 1980s human cases are confirmed through blood tests. No deaths or hospitalizations are reported, but studies consistently show widespread human exposure to the virus.

The disease is mapped as it moves from Uganda to western Africa and Asia in the first half of the 20th century. In 1969 – 1983 Zika virus is detected in mosquitoes found in equatorial Asia, including India, Indonesia, Malaysia and Pakistan.

In 2007 first large Zika outbreak in humans in the Pacific Island of Yap in the Federated States of Micronesia. Prior to this, no outbreaks and only 14 cases of human Zika virus disease had been documented anywhere in the world. An estimated 73% of Yap residents are infected with Zika virus.

IN 2008 a US scientist conducting field work in Senegal falls ill with Zika infection. On his return home to Colorado he infects his wife in what is the first documented case of sexual transmission of a disease usually transmitted by insects. In 2012 researchers identify 2 distinct lineages of the virus, African and Asian. In 2013 – 2014 outbreaks occur in 4 other groups of Pacific islands: French Polynesia,

Easter Island, the Cook Islands, and New Caledonia. Thousands of suspected infections are investigated in French Polynesia and results reveal possible associations between Zika virus and congenital malformations and severe neurological and autoimmune complications.

In 20 March 2014 during the outbreak of Zika virus in French Polynesia, 2 mothers and their newborns are found to have Zika virus infection within 4 days of birth. The infants' infections appear to have been acquired by transplacental transmission or during delivery. In 31 March 2014 during the same outbreak of Zika virus in French Polynesia 1,505 asymptomatic blood donors are reported to be positive for Zika by PCR. These findings alert authorities that Zika virus can be passed on through blood transfusion. In 29 March 2015 Brazil notifies WHO of an illness characterized by skin rash in northeastern states.

In 17 July 2015 Brazil reports neurological disorders associated with a history of infection, primarily from the north-eastern state of Bahia. Among these reports, 49 cases were confirmed as Guillain-Barré syndrome. Of these cases, all but 2 had a prior history of infection with Zika, chikungunya or dengue.

Brazil reports an unusual increase in the number of cases of microcephaly among newborns. On 17 November 2015 WHO issue an epidemiological alert asking countries to report increases of congenital microcephaly and other central nervous system malformations. Brazil reports the detection of Zika virus in amniotic fluid samples from 2 pregnant women, whose foetuses were confirmed by ultrasound examinations to have microcephaly. In 28 November 2015 Brazil detects Zika virus genome in the blood and tissue samples of a baby with microcephaly and other congenital anomalies; the baby died within 5 minutes of birth. Brazil reports 3 deaths among 2 adults and a newborn associated with Zika infection. On 1 December 2015 WHO issue an alert on the association of Zika virus infection with neurological syndrome and congenital malformations in the Americas.

In 5 January 2016 researchers report the first diagnoses of intrauterine transmission of the Zika virus in 2 pregnant women in Brazil whose fetuses were diagnosed with microcephaly, including severe brain abnormalities, by ultrasound. Although tests of blood samples from both women are negative, Zika virus is detected in amniotic fluid.

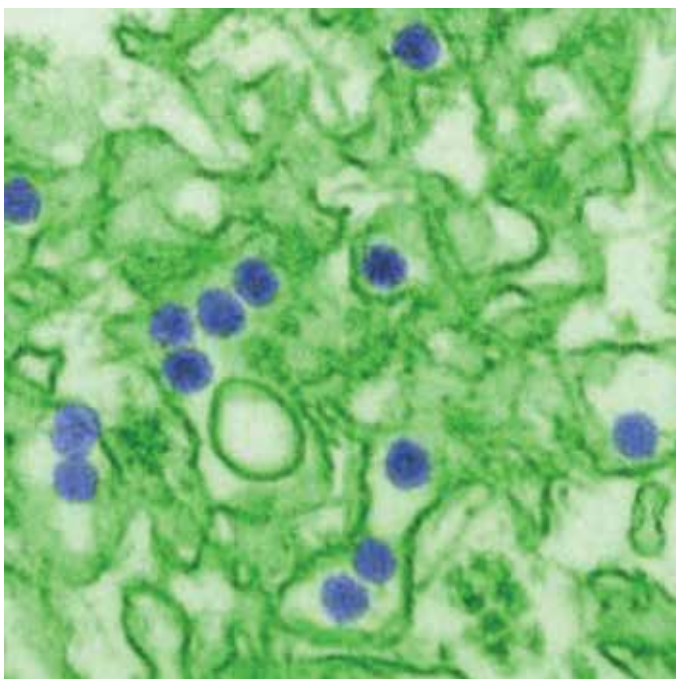


Fig. 1: Electron micrograph of the virus. Virus particles (digitally colored purple) are 40 nm in diameter, with an outer envelope and a dense inner core

In 7 January 2016 Ophthalmologists in Brazil report severe ocular malformations in 3 infants born with microcephaly. In 12 January 2016 in collaboration with health officials in Brazil, the United States Centers for Disease Control and Prevention release laboratory findings of 4 microcephaly cases in Brazil (2 newborns who died in the first 24 hours of life and 2 miscarriages) which indicate the presence of Zika virus RNA by PCR and by immunohistochemistry of brain tissue samples of the 2 newborns. In addition, placenta of the 2 fetuses miscarried during the first 12 weeks of pregnancy test positive by PCR. Clinical and epidemiological investigations in Brazil confirm that all 4 women presented fever and rash during their pregnancy. The findings are considered the strongest evidence to date of an association between Zika infection and microcephaly.

In 19 January 2016 El Salvador reports an unusual increase of Guillain–Barré syndrome.

In 22 January 2016 Brazil reports that 1,708 cases of Guillain–Barré syndrome have been registered by hospitals between January and November 2015. Most states reporting cases are experiencing simultaneous outbreaks of Zika, chikungunya, and dengue. In 27 January 2016 French Polynesia reports retrospective data on its Zika outbreak, which coincided with a dengue outbreak. During the outbreak, 42 cases of Guillain–Barré syndrome were diagnosed - a 20-fold increase over previous years. All 42 cases tested positive for Zika and dengue. The investigation concluded that successive dengue and Zika virus infections might be a predisposing factor for developing Guillain–Barré syndrome.

In 2 February 2016 the United States reports a case of sexual transmission of Zika infection in Texas. Venezuela

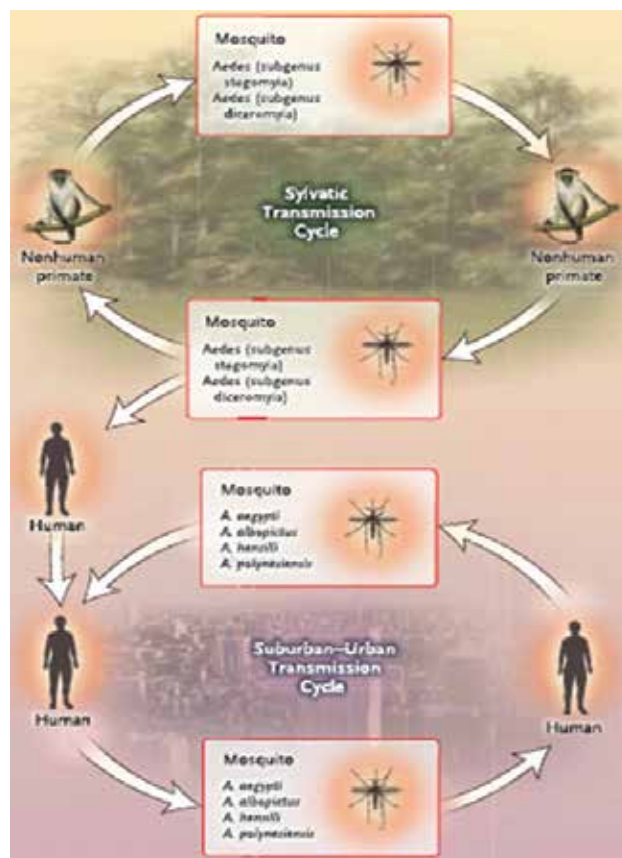


Fig. 2: Zika Virus Transmission Cycle

reports an increase in cases of Guillain–Barré syndrome (GBS) since the second week of January 2016. By end January 2016, 252 GBS cases, associated in time and place with Zika, are reported.

In 4 February 2016 Brazilian health officials confirm a case of Zika virus infection transmitted by transfused blood from an infected donor. In 7 February 2016 Suriname reports an increase in Guillain–Barré syndrome, beginning in 2015, with 10 cases of Guillain–Barré syndrome positive for Zika. In 10 February 2016 a case report describes severe fetal brain injury associated with Zika virus infection in a woman who became pregnant in Brazil in February 2015. No virus or pathological changes were found in any other organs, suggesting that the virus is strongly neurotropic, which means it preferentially attacks the nervous system. Honduras reports at least 37 Guillain–Barré syndrome cases in 2016.

The report brings the number of countries detecting an increase in GBS associated with Zika virus circulation to 8: French Polynesia, Brazil, El Salvador, the French territory of Martinique, Colombia, Suriname, Venezuela, and Honduras.

In 3 March 2016 a case report published online in the Lancet describes a 15-year-old Zika-positive girl in Guadeloupe who developed acute myelitis (inflammation of the spinal cord), which caused severe back pain, numbness, and bladder dysfunction. This association suggests that Zika virus preferentially affects the nervous system. In 4 March 2016 a study in Brazil of 88 pregnant women

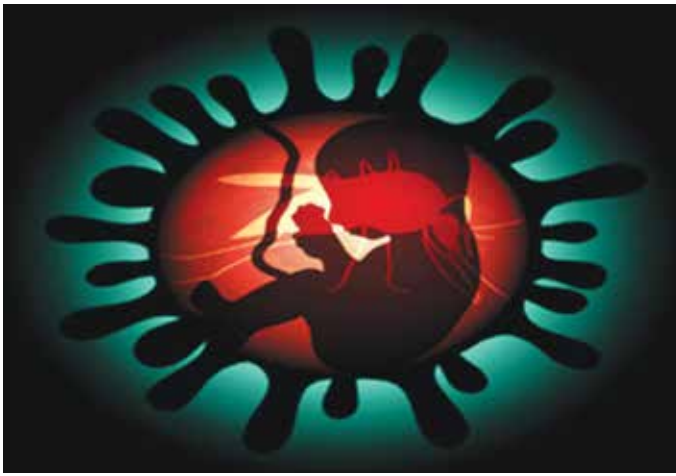

Fig. 3: Transplacental Transmission

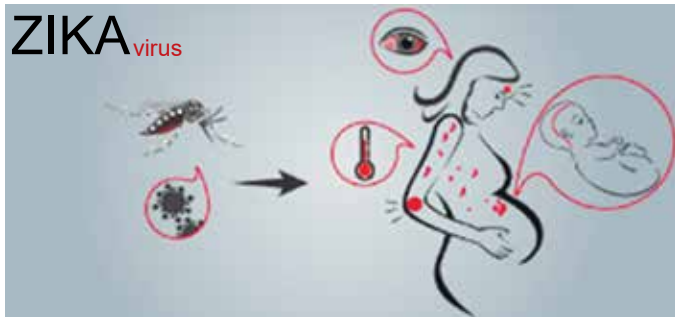


Fig. 4: Transmission from Mother to Foetus

found that 72 women tested positive for Zika virus in their blood and/or urine. Abnormalities of the fetus were detected by ultrasound in 12 Zika-positive women. These findings add to the growing body of evidence linking Zika virus infection to fetal abnormalities. In 10 March 2016 the United States reports 2 GBS cases with confirmed Zika virus infection. The first case, an elderly man with a recent history of travel to El Salvador, died from sudden subarachnoid haemorrhage caused by a ruptured aneurysm. The second case, a male resident of Haiti in his 30s, was diagnosed after he travelled to the US for treatment. He recovered fully after 5 days of treatment in hospital.

ZIKA VIRUS TRANSMISSION

Mosquito – Borne Transmission

Zika virus exists in a sylvatic transmission cycle involving nonhuman primates and forest-dwelling species of aedes mosquitoes. Figure 1 shows the electron micrograph of the virus. In Asia, a sylvatic transmission cycle has not yet been identified. In urban and suburban environments, Zika virus is transmitted in a human-mosquito-human transmission cycle (Figure 2). Two species in the stegomyia subgenus of aedeses - *A. aegypti* and, to a lesser extent, *A. albopictus* – have been linked with nearly all known Zika virus out-breaks. *A. aegypti* is thought to have high vectorial capacity (i.e, the overall ability of a vector species to transmit a pathogen in a given location and at a specific time) because it feeds primarily on humans, often bites multiple humans in a single blood meal, has an almost imperceptible bite, and lives in close association with human habitation.

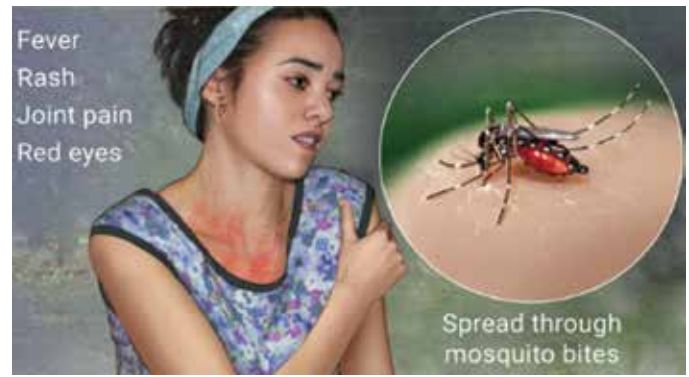

Fig. 5: Symptoms of Zika Virus

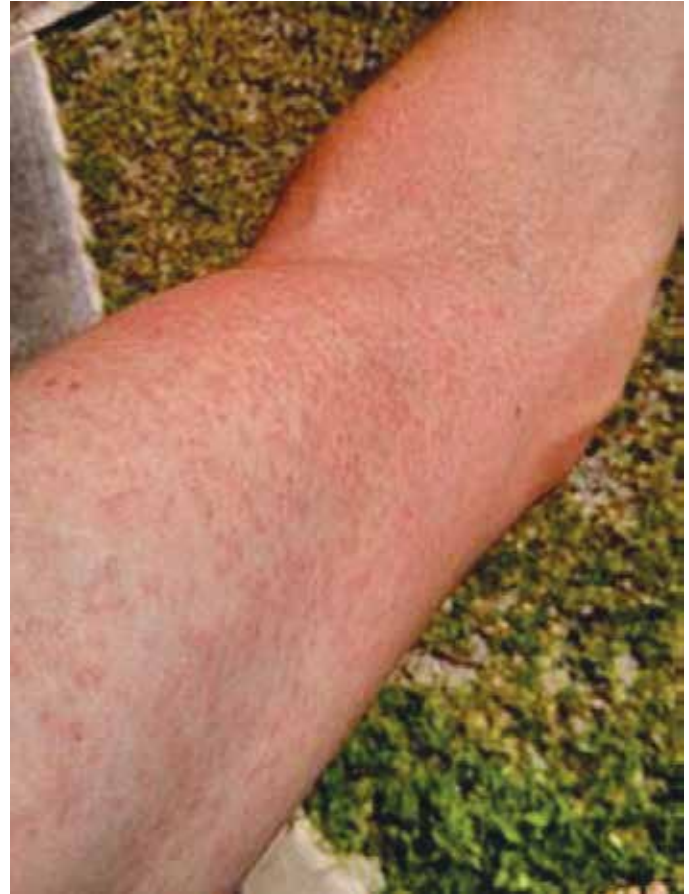

Fig. 6: Rash on an arm due to ZIKA

Nonmosquito Transmission

Substantial evidence now indicates that Zika virus can be transmitted from the mother to the foetus during pregnancy and peripartum transmission of Zika have been reported among mother-infant pairs (Figures 3 and 4).

Sexual transmission to partners of returning male travelers who acquired Zika virus infection abroad has been reported. Replicative viral particles, as well as viral RNA – often in high copy numbers – have been detected up to 62 days after the onset of symptoms. Male-to-male transmission reported from Texas in January 2016. Transmission of Zika virus through blood transfusion has been reported. Transmission of Zika virus occurred after a monkey bite in Indonesia. Transmission through on breast milk has not been documented, although the

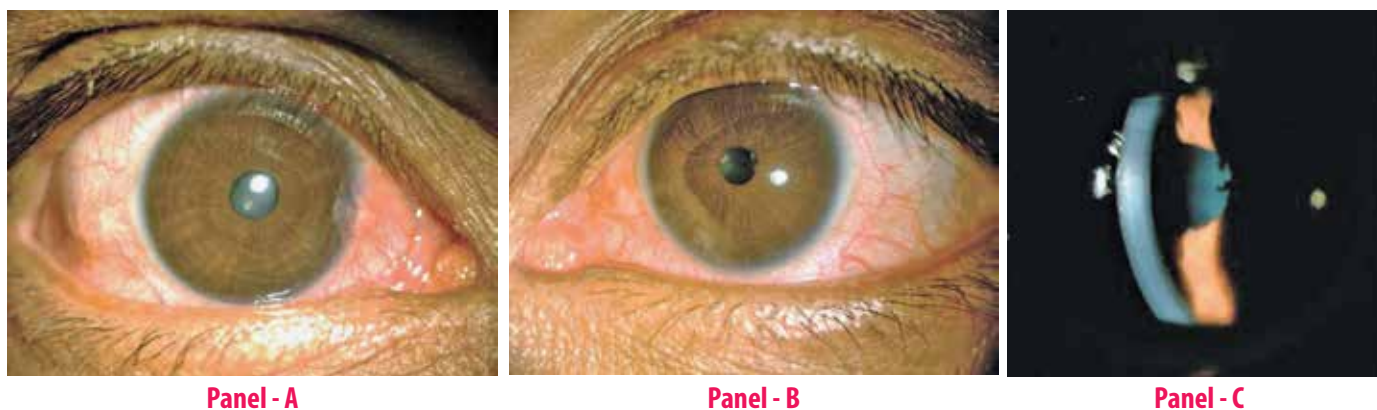


Fig. 7: Slit-Lamp Photographs of The Patient's Eyes. Conjunctival hyperaemia in the right eye (Panel – A) and left eye (Panel – B) 8 days after the onset of systemic symptoms. Panel – C, are keratic precipitates and grade 2+ inflammatory cells in the anterior chamber of the left eye 16 days after the onset of Zika virus infection`

breast milk of a woman who became symptomatic with Zika virus infection on the day of the delivery contained infective Zika viral particles in high titer.

CLINICAL PRESENTATION

The incubation period for Zika virus is unknown, but if it is similar to that of other mosquito borne flaviviruses, it is expected to be generally less than one week (average 3 to 10 days).

The most common symptoms of Zika virus disease are fatigue, chills, loss of appetite, or sweating, rash which is maculopapular and pruritic (90% of patients), fever when present, is generally short-term and low-grade (65%), arthritis or arthralgia (65%), non-purulent conjunctivitis (55%), myalgia (48%), headache (45%), retro-orbital pain (39%), oedema (19%), and vomiting (10%). Other symptoms include haemospermia, transient dull and metallic hearing, swelling of hands and ankles, and subcutaneous bleeding (Figures 5 and 6).

SYSTEMIC MANIFESTATION

Neurologic Complications

A temporal and geographic relationship has been observed between Guillain-Barre' syndrome and Zika virus outbreaks in the Pacific and the Americas. A case-control study in French Polynesia revealed a strong association (odds ratio, >34) between Guillain-Barre' syndrome and previous Zika virus infection; the findings from electrophysiological studies were compatible with the acute motor axonal neuropathy subtype of Guillain-Barre' syndrome. Meningoencephalitis and acute myelitis complicating Zika virus infection also have been reported. Brazilian scientists said they had discovered a new neurologic disorder associated with Zika virus infections in adults, an autoimmune syndrome called acute disseminated encephalomyelitis. Resembling multiple sclerosis and found mostly in children, acute disseminated encephalomyelitis attacks nerve fibers in the brain and spinal cord.

ADVERSE FOETAL OUTCOMES

The findings of Zika virus RNA in amniotic fluid of fetuses with microcephaly and in the brain tissue of

foetuses and infants with microcephaly, as well as the high rates of microcephaly among infants born to mothers with proven antecedent acute Zika virus infection, provide strong evidence linking microcephaly to maternal Zika virus infection. The greatest risk of microcephaly is in the first trimester.

In addition to microcephaly, an absent corpus callosum, hydranencephaly, cerebral calcifications, ventricular dilatation, brain atrophy, and abnormal gyration, hydrops foetalis, anhydramnios, and intrauterine growth retardation have been found.

OCULAR MANIFESTATION

The most common ocular abnormalities were focal pigment mottling, chorioretinal atrophy, and optic nerve abnormalities (hypoplasia and severe cupping of the optic disk). Other ocular manifestations include foveal reflex loss, macular neuroretinal atrophy, lens subluxation, and iris coloboma (Figure 7).

REFERENCES

1. Deckard DT, Chung WM, Brooks JT, et al, Male-to-male transmission of Zika virus – Texas, January 2016. *MMWR Morb Mortal Wkly Rep* 2016; 65:372-374.
2. Hughes S, "Zika virus now linked to autoimmune neurologic condition," Published April 12, 2016.
3. Goodman B. CDC: " Zika virus definitely causes microcephaly. " Published April 13, 2016
4. Centers for Disease Control and Prevention. *Zika Virus* 2015. <http://www.cdc.gov/zika/index.html>.
5. World Health Organization. Zika virus infection e Brazil and Colombia. 21 Oct 2015. <http://www.who.int/csr/don/21-october-2015-zika/en/>.
6. Duffy MR, Chen TH, Hancock WT, Powers AM, Kool JL, Lanciotti RS, et al. Zika virus outbreak on Yap island, Federated States of Micronesia. *N Engl J Med* 2009; 360:2536e43.
7. Dupont-Rouzeyrol M, O'Connor O, Calvez E, Daures M, John M, Grangeon JP, et al. Co-infection with Zika and dengue viruses in 2 patients, New Caledonia, 2014. *Emerg Infect Dis* 2015; 21:381e2.
8. Oehler E, Watrin L, Larre P, Leparac-Goffart I, Lastere S, Valour F, et al. Zika virus infection complicated by Guillain-

Barre syndrome e case report, French Polynesia, December 2013. *Euro Surveill* 2014; 19. Pii 20720.

9. European Centre for Disease Prevention and Control. Rapid risk assessment: microcephaly in Brazil potentially linked to the Zika virus epidemic. 24 Nov 2015. <http://ecdc.europa.eu/en/publications/Publications/zika-microcephaly-Brazil-rapid-risk-assessment-Nov-2015.pdf>.
10. World Health Organization. Zika virus infection e suriname. 13 Nov 2015. <http://www.who.int/csr/don/13-november-2015-zika/en/>.
11. European Centre for Disease Prevention and Control. Zika virus infection: factsheet for health professionals. 2015. http://ecdc.europa.eu/en/healthtopics/zika_virus_infection/factsheet-health-professionals/Pages/factsheet_health_professionals.aspx.
12. Foy BD, Kobylinski KC, Chilson Foy JL, Blitvich BJ, Travassos da Rosa A, Haddock AD, et al. Probable nonevector-borne transmission of Zika virus, Colorado, USA. *Emerg Infect Dis* 2011;17:880e2.
13. World Health Organization and Pan American Health Organization. Zika Virus (ZIKV) surveillance in the Americas: interim guidance for laboratory detection and diagnosis. 2015. Available at: http://www.paho.org/hq/index.php?option=com_topics&view=article&id=4427&Itemid=41484&lang=en.
14. Epidemiological Alert Neurological syndrome, congenital malformations, and ZIKA virus infection. Implications for public health in the Americas: 1 December 2015