

INTRODUCTION

The term arthritis literally means joint pains associated with joint inflammation, synovial thickening and eventually joint erosions leading to a deforming and debilitating disease. The classic example we see in our day to day practice is Rheumatoid Arthritis (RA). It was recognized in the early part of the 20th century that not all cases of inflammatory arthritis were homogeneous in presentation. The ability to apply the rheumatoid factor (RF) test more widely in the 1950s helped confirm that not all inflammatory arthritis were seropositive. Therefore, the term, seronegative variants of rheumatoid arthritis, was introduced. Our aim in this chapter is to provide concise information about the various types of seronegative arthritis and to focus on the approach for its evaluation.

ETIOLOGY OF SERONEGATIVE ARTHRITIS

Although no clear-cut definition exists, the following differential diagnoses should be considered:

1. Seronegative rheumatoid arthritis
2. The Spondyloarthritides
3. Crystalline arthropathies
4. Infectious diseases
5. Neoplastic/paraneoplastic arthritis
6. Inflammatory/ connective tissue disease

Seronegative arthritis may be differentiated into inflammatory versus non-inflammatory. Furthermore seronegative inflammatory arthritis may be divided into monoarthritis (single joint involvement), oligoarthritis (2, 3 or 4 joints involved) or polyarthritis (> 5 joints).

SERONEGATIVE RHEUMATOID ARTHRITIS

IgM, IgG and IgA isotypes of RF occur in sera from patients with RA, although the IgM isotype is the one most frequently assessed. Around 20-25 % of RA patients may test negative for RF and yet have the full clinical picture with the potential for poor prognosis when not treated. It is important to remember that some patients with RA may take 18-24 months to become seropositive. In 2010, a collaborative effort between the American College of Rheumatology (ACR) and the European League Against Rheumatism (EULAR) revised the 1987 ACR classification criteria for RA in an effort to improve early diagnoses with the goal of identifying patients who would benefit from early introduction of disease modifying therapy. The new criteria include a positive test for serum anti-CCP

antibodies (ACPA), which carries greater specificity for the diagnosis of RA than a positive test for RF. In early RA, the specificity of ACPA ranges from 94-100%, compared with RF in which the specificity ranges from 23-96%. By the same rule patients should also be negative for ACPA in order to be labeled as seronegative RA. Seronegative patients are often regarded as having a milder set of symptoms compared to seropositive patients. Generally, seronegative patients don't develop rheumatoid nodules as these are commonly displayed in seropositive patients. This is never a certainty, however, and each patient's symptoms and progression will differ. We know that seropositive RA has strong association with HLA- DR4 but its relation in seronegative RA is controversial.

THE SPONDYLOARTHRITIDES

This group of disorders encompass ankylosing spondylitis (AS), psoriatic arthritis, reactive arthritis, enteropathic arthritis, juvenile onset spondyloarthritis (SpA) and undifferentiated spondyloarthropathy. Some of the important differentiating features amongst these are listed in Table 1.

All of these have some distinct as well as some overlapping features, characteristic axial involvement and a negative rheumatoid factor. Involvement of peripheral joints is usually oligoarticular but rarely polyarthritis may be present.

The typical characteristic features of these seronegative SpAs are:

1. Asymmetric peripheral arthritis predominantly of lower limbs and inflammatory back pain (IBP).
2. Radiographic sacroiliitis with or without spondylitis
3. Enthesopathy.
4. Absence of rheumatoid factor or other features of RA
5. Anterior uveitis
6. Increased familial incidence
7. Presence of dactylitis
8. Association with HLA B27- The incidence and prevalence of AS generally mirrors the frequency of HLA-B27 in the population. The risk of developing AS in healthy HLA-B27 positive subjects is approximately 6% in various population groups.

In India, the prevalence was found to be 0.6% in a study done in South India.

Table 1: Features of spondyloarthritides

Features	Ankylosing spondylitis	Reactive arthritis	Psoriatic arthritis	Enteropathic arthritis
Age of onset	20-30 years	20-30 years	35-45 years	Any age
Male:female ratio	3:1	5:1	1:1	1:1
Peripheral arthritis	Asymmetrical lower extremities	Asymmetrical lower extremities	Any joints	Asymmetrical lower extremities
Spine involvement	Symmetrical sacroiliitis (100%), delicate marginal Syndesmophytes : lumbar spine and lower thoracic spine involved initially	Asymmetrical sacroiliitis, bulky marginal syndesmophytes	Asymmetrical sacroiliitis, bulky marginal syndesmophytes: cervical spine involvement most commonly	Symmetrical sacroiliitis, delicate marginal syndesmophytes
Enthesitis	Uncommon	Common	Common	Less Common
Dactylitis	Uncommon	Common	Common	Uncommon
Dermatological manifestations	Non-specific	Keratoderma blennorrhagica, circinate balanitis	Psoriasis	Erythema nodosum, pyoderma gangrenosum
Uveitis	Occasional	Common	Occasional	Occasional
Other extra-articular manifestations	Aortic regurgitation, conduction defects, upper lobe pulmonary fibrosis, IgA nephropathy	Aortic regurgitation	Aortic regurgitation	Aortic regurgitation
Familial aggregation	Common	Common	Common	Common
HLA B27	90%	80%	40%	30%

Table 2: Criteria for Ankylosing Spondylitis

Adapted from the Modified New York criteria 1984 for ankylosing spondylitis

Clinical criteria

- Low back pain and stiffness for longer than 3 months, which improve with exercise, but are not relieved by rest
- Restriction of motion of the lumbar spine in both the sagittal and frontal planes
- Restriction of chest expansion relative to normal values correlated for age and sex

Radiological criterion

- Sacroiliitis grade ≥ 2 bilaterally, or grade 3–4 unilaterally

Progressive damage due to continuous inflammation and osteoproliferation rather than osteodestruction leads to loss of spinal mobility which can be assessed by Schober's test. Syndesmophytes, ankylosis and eventually fibrosis are the most characteristic features of this disease.

Definite ankylosing spondylitis is present if the radiological criterion is associated with at least one clinical criterion (Table 2).

The characteristic radiological features of AS are shown in Figure 1.

CRYSTALLINE ARTHROPATHIES

Gout is the most common of the crystal induced arthritis. It is usually a chronic disease with acute flares. Underexcretion is the cause in 85–90% patients (excretion < 330 mg/dl) whereas overproduction is the cause in 10% people with hyperuricemia (HU). Prevalence of HU ranges between 2.6% to 47.2% worldwide. Asymptomatic hyperuricemia is present when serum uric acid (SUA) is higher than 6.8 mg/dl (>7 mg/dl in adult males and >6 mg/dl in adult females). Only 10% of patients with HU will develop gout and the incidence increases with increasing levels of SUA and the duration for which they remain elevated. At the end of 5 years incidence increases by 10% and 22% if the SUA levels are respectively above 8mg/dl and 9mg/dl. As the duration and levels increase, inflammation and gradually structural damage occurs in the joints (Figure 2).

Typical clinical presentation is acute monoarthritis involving first metatarsophalangeal joint typically called Podagra. However gout may present as oligoarthritis involving the midtarsal, ankle, knee, wrist or elbow joints. The oligoarticular subacute presentation is usual in elderly and may make the diagnosis confusing, serum uric acid (SUA) is elevated but may be even normal in 30% of the acute gout cases and should be repeated after 2 weeks. Synovial fluid (SF) aspiration showing monosodium urate (MSU) crystals which are negatively birefringent on polarizing microscope is the definitive

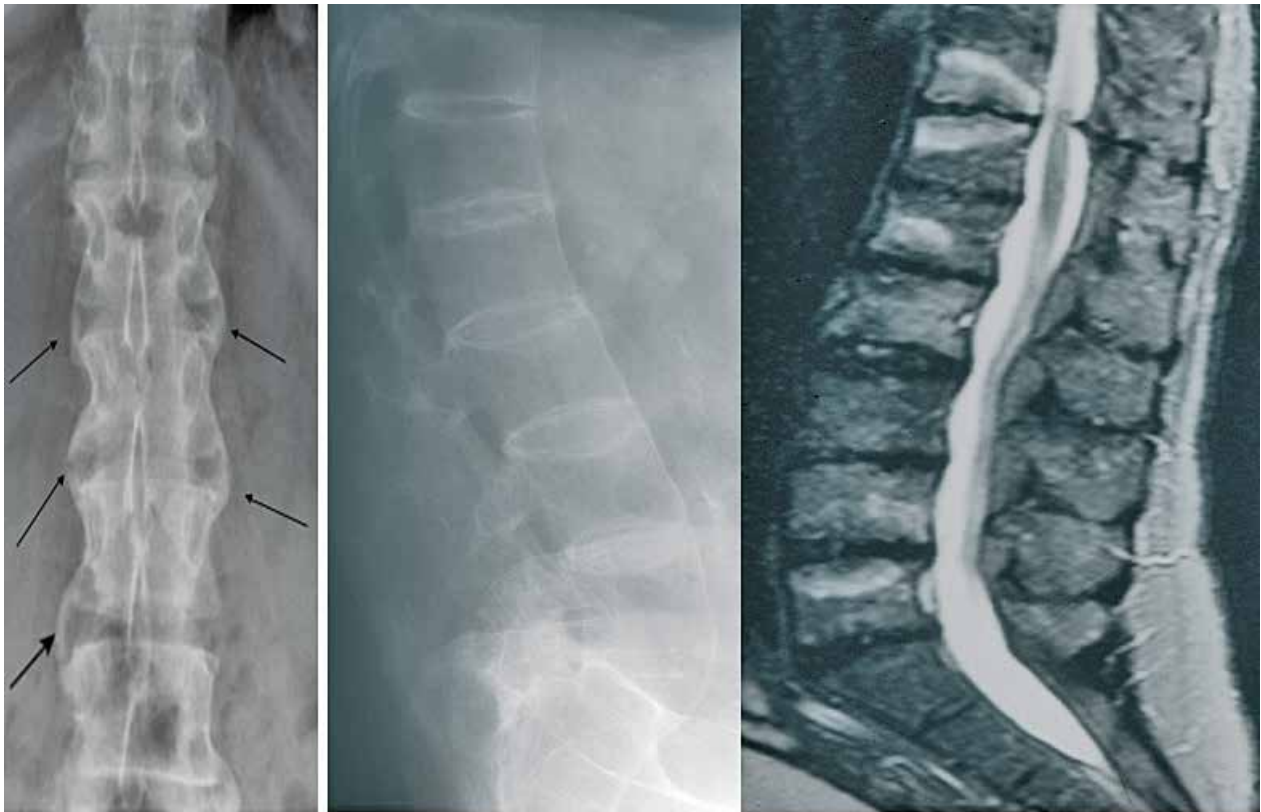

Fig. 1: X-ray of patient with AS showing Syndesmophytes (arrows) (left) and middle resulting in bamboo spine. Right sided T2 weighted MRI image showing spondylitis and spondylodiscitis

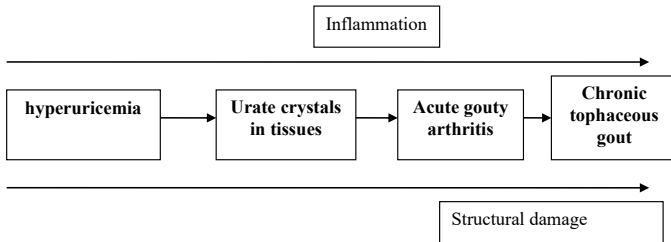


Fig. 2: Gout occurring via four sequence of changes from hyperuricemia

evidence of gout. A diagnosis of tophaceous gout may be suggested by classic erosions with overhanging edges in plain x-rays. The presence of chondrocalcinosis at the triangular fibrocartilage or menisci of knees is suggestive of calcium pyrophosphate deposition disease (CPPD). Synovial calcification may also be seen at the MCP and MTP joints, wrist and knees.

INFECTIOUS DISEASE

Infectious arthritis should be considered in any acute monoarticular joint involvement, especially in the presence of fever. Risk factors include: >80 years of age, diabetes mellitus, rheumatoid arthritis, joint surgery, hip or knee prosthesis, skin infection, and human immunodeficiency virus infection.

Staphylococcus aureus is still the most common organism associated with septic arthritis. With increase of intravenous drug abuse, we are seeing more of Methicillin Resistant *Staphylococcus aureus* (MRSA). *Streptococcus* spp, *Neisseria gonorrhoeae*, *Klebsiella*

pneumoniae, *Pseudomonas*, *Fusobacterium necrophorum* mycobacteria, spirochetes, fungi, and viruses are the other organisms isolated. The major consequence of bacterial invasion is damage to articular cartilage by bacterial proteases as well as host response by leucocyte invasion.

Bacterial septic arthritis usually involves one large joint of the body especially knee or hip. Polyarticular disease is only seen in 10 – 20% patients, usually those with underlying RA. Acute septic arthritis presents with a single hot, swollen, red and tender joint is shown in Figure 3.

Gonococcal infection is by far the most common cause of monoarthritis or oligoarthritis in young sexually active adults, with a female/male ratio of 3:1. Gonococcal arthritis results from blood dissemination of *Neisseria gonorrhoeae* from primary sexually acquired mucosal infection. It has a characteristic clinical triad of migratory polyarthralgia, dermatologic lesions (presenting as macules and papules) and tenosynovitis often affecting multiple joints simultaneously (particularly wrists, fingers, ankles, and toes), as well as systemic inflammatory symptoms. Clinical characteristics of gonococcal and nongonococcal arthritis are summarized in Table 3.

Diagnostic clue may be provided by acute phase reactants, leucocytosis but definitive diagnosis needs joint aspiration and direct identification of the culprit bacteria. Blood cultures should be taken. In bacterial septic arthritis, synovial fluid is turbid with high leucocyte count and low glucose. Both aerobic and anaerobic cultures of SF

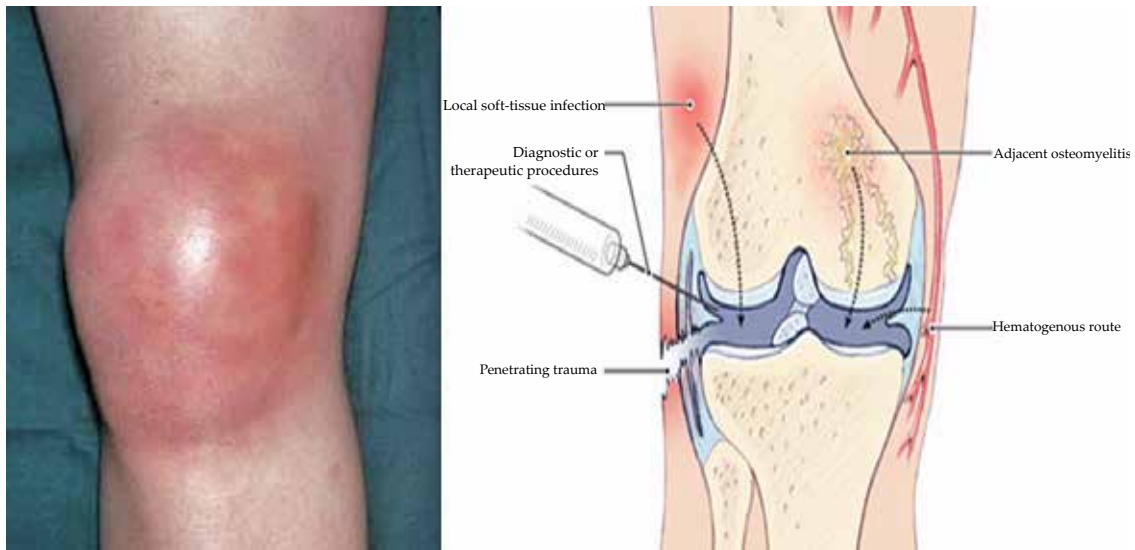


Fig. 3: Showing a typical red, hot and swollen knee joint (left) and internal structure of that joint (right) in a patient with septic arthritis

Table 3: Clinical characteristics of gonococcal and nongonococcal arthritis

Characteristics	Gonococcal	Nongonococcal
Patient profile	Sexually active young adults, mainly women	Newborns or adults with chronic disease (diabetes, RA, OA)
Presentation	Migratory polyarthralgias dermatitis, tenosynovitis	Single joint involvement
Pattern of joint involvement	Usually mono or oligoarticular	Rarely Oligoarticular or polyarticular
Culture positivity	Less than 50%	Nearly 90%
Prognosis	Good with adequate antibiotic therapy	Usually bad prognosis, needs good antibiotics plus joint drainage

are gold standards for diagnosis. Imaging studies can identify acute or chronic osteomyelitis.

Septic arthritis is an emergency requiring aggressive approach with early antibiotics and drainage of the purulent material. Early team approach can prevent permanent deformity, disability and mortality which in monoarthritis is as high as 11 percent.

Apart from pyogenic septic arthritis it is important to remember that musculoskeletal involvement could be because of tuberculosis in 1% - 3% of all cases and almost half of them involve the spine. Osteoarticular lesions occur due to hematogenous spread from primary focus.

Arthritis related to hepatitis B virus (HBV) infection may present as acute polyarthritis related to acute infection. Hepatitis C virus (HCV) infection commonly causes polyarthralgia but is often associated with a positive RF. Parvovirus B19 infection presents acutely with polyarticular symmetric arthralgia without significant swelling. Before highly active antiretroviral therapy (HAART), rheumatic manifestations of HIV infection included HIV-associated arthritis, reactive arthritis, psoriatic arthritis, and painful articular syndrome. However, the spectrum of disease has significantly changed with HAART therapy, and a syndrome

resembling rheumatoid arthritis, SLE, or polymyositis may emerge de novo.

NEOPLASTIC / PARANEOPLASTIC ARTHRITIS

Primary tumors and tumor like disorders of synovium are uncommon but should be considered in the differential diagnoses of monoarticular joint disease. In addition, metastases to bone and primary bone tumors adjacent to a joint may produce joint symptoms. Pigmented villonodular synovitis (PVNS) is characterized by the slowly progressive, exuberant, benign proliferation of synovial tissue usually involving a single joint. Clinically it presents as insidious onset of arthritis usually involving the knees. Synovial chondromatosis is another disorder characterized by multiple focal metaplastic growths of cartilage in the synovium or tendon sheaths.

Paraneoplastic arthritis has been described and may occur in several patterns: asymmetric disease involving the lower extremity joints and symmetric polyarthritis with hand joint involvement. It is most commonly seen with breast, colon, lung, ovarian, gastric cancers and lymphoproliferative disorders.

INFLAMMATORY / CONNECTIVE TISSUE DISORDERS

Most people with systemic lupus erythematosus (SLE) have intermittent polyarthritis characterized by soft tissue

Table 4: Differential diagnosis of Seronegative Arthritis

Symptom or sign	Differential diagnosis
Temperature >40°C (>104°F)	Juvenile-onset or adult-onset idiopathic arthritis, bacterial arthritis, SLE
Fever preceding arthritis	Viral arthritis, Lyme arthritis, reactive arthritis, juvenile-onset or adult-onset idiopathic arthritis, bacterial endocarditis
Migratory arthritis	Rheumatic fever, disseminated gonococcal or meningococcal infection, viral arthritis, SLE
Pain out of proportion to effusion	Rheumatic fever, acute leukemia, AIDS
Effusion greater than pain	Tuberculous arthritis, subacute bacterial endocarditis, enteropathic arthritis, giant cell arteritis, Lyme disease
Leukopenia	SLE, viral arthritis
Episodic recurrences	Lyme disease, crystal-induced arthritis, enteropathic arthritis, Whipple's disease, juvenile-onset or adult-onset idiopathic arthritis, SLE

swelling and tenderness most commonly in hands, wrists and knees. Joint deformities develop in only 10%. Some individuals have rheumatoid like arthritis with erosions

and fulfill criteria for both RA and SLE (rhumus); they may be labeled as having both diseases.

Varied presentation involving the musculoskeletal systems may be seen in other multisystemic diseases like polymyositis, scleroderma, overlap syndromes, sarcoidosis and systemic vasculitis.

On the basis of clinical symptoms and signs, Table 4 shows some of the common differential diagnosis.

REFERENCES

- Handa R. Approach to Seronegative Arthritis. *JACM* 2003; 4:190-192.
- Aletaha D, Neogi T, Silman AJ, Funovits J, Felson DT, Bingham CO III et al. 2010 Rheumatoid Arthritis Classification Criteria. An American Collage of Rheumatology/European League Against Rheumatism Collaborative Initiative. *Arthritis Rheum* 2010; 62:2569-2581.
- Garcia- Arias M, Perez – Esteban S and Castaneda S. Septic Arthritis and Tuberculosis Arthritis. *J Arthritis* 2012; 1:102.
- Garcia – De da Torre L, Nava – Zavala A. Gonococcal and Nongonococcal arthritis. *Rheum Dis Clin North Am* 2009; 35:63–73.
- Tuli SM. General Principles of Osteoarticular Tuberculosis. *Clin Orthop n Relat Res* 2002; 11–19.
- Garg RK and Somvanshi DS. Spinal Tuberculosis: A Review. *J Spinal Cord Med* 2011; 34:440–454.
- Saigal R and Agrawal A. Pathogenesis and Clinical Management of Gouty Arthritis. *J Assoc Physicians India* 2015; 63:56-63.
- Harrison's Principles of Internal Medicine 19th Ed. McGraw- Hill Education, 2015; 2246-2247.
- Malaviya AN, Sawney S, Mehra NK and Kanga U. Seronegative Arthritis in South Asia: An Up-to-date Review. *Curr Rheumatol Rep* 2014; 16:413.
- Londhey V, Satija T. Hyperuricemia: Relevance in Clinical practice. *Medicine Update* 2016; 1:103–106.