

- Coma is a state of unconsciousness caused by temporary or permanent impairment of the ascending reticular system in the brainstem, or both cerebral hemispheres.

The key components of the neurological examination of the comatose patient are:

- level of consciousness
- the pattern of breathing
- size and reactivity of the pupils
- eye movements and oculovestibular responses
- motor responses (tone, reflexes and posturing)
- meningism and signs of the underlying cause

In particular, assessment of asymmetry for the presence of focal neurological deficits is vital.

## CAUSES OF COMA

While stabilizing the ABCs, watch for any focal deficit.

### CAUSES WITH FOCAL SIGNS

- No meningism — stroke, space occupying lesions (e.g. tumor, hemorrhage, abscess), injury, inflammation
- Meningism — meningoencephalitis, subarachnoid hemorrhage (SAH)

### CAUSES WITHOUT FOCAL SIGNS

- Toxins
- Organ failures
- Metabolic - (CO<sub>2</sub>, O<sub>2</sub>, ammonia, temperature, pH, electrolytes, glucose, serum osmolality)
- Endocrine
- Seizures

Systemic causes can sometimes have focal signs (e.g. Todd's paresis, hemiparesis due to hypoglycemia)

## GENERAL EXAMINATION

General examination is very important

- Consider the neurological findings in light of the vital signs, evidence of trauma, acute or chronic illness, and/or drug ingestion
- Are there signs of trauma, such as a battle sign (bruising of the mastoid bone) or raccoon eyes (periorbital ecchymosis), which may each suggest

skull base fractures.

- Cranial scars, drains, ICP monitors and VP shunts
- Track marks and drug paraphernalia
- Infusions (e.g. Sedatives, vasopressors)
- Ventilator (evidence of spontaneous breaths)

## IMPORTANT SIGNS AND DIAGNOSTIC CONSIDERATIONS

### Vital Signs

- Hypertension- Pheochromocytoma, eclampsia, calcineurin inhibitor toxicity, drug ingestion (amphetamines, arsenic, cocaine, phencyclidine).
- Hypotension - Addison disease, sepsis, drug ingestion ( $\beta$  blockers, calcium channel blockers, arsenic, barbiturates, cyclic antidepressants, lithium, methanol, opioids, organophosphates, phenothiazine, sedative-hypnotics)
- Hypothermia - Hypothyroidism, hypoglycemia, environmental exposure, drug ingestion (barbiturates, opioids, sedative-hypnotics, phenothiazine)
- Hyperthermia - Infection, drug ingestion (amphetamines, cocaine, tricyclic antidepressants, phencyclidine, salicylates), malignant catatonia, neuroleptic malignant syndrome
- Tachycardia - Infection, drug ingestion (alcohol, amphetamines, cocaine, ethylene glycol, arsenic, cyclic antidepressants, phencyclidine, phenothiazine)
- Bradycardia - Uremic coma, myxedema coma, drug ingestion ( $\beta$  blockers, opioids)
- Tachypnea - Diabetic ketoacidosis, drug ingestion (ethylene glycol, salicylates, amphetamines, methanol)
- Dyspnea - ACS, Drug ingestion (alcohol, barbiturates, opioids, sedative-hypnotics)

### Odour

- Dirty restroom - Uremia
- Fruity sweat- Ketoacidosis
- Musty or fishy - Acute hepatic failure
- Garlic - Organophosphates, insecticides, thallium
- Onion - Paraldehyde

## Skin

- Diaphoresis - Thyroid storm, hypoglycemia, malignant catatonia, acute sympathetic hyperactivity, drug exposure (organophosphates, sympathomimetics, cholinergics)
- Dry skin - Hypothyroidism, drug exposure (barbiturates, anticholinergics, cyclic antidepressants)
- Acne - Long-term antiepileptic use
- Bullae - Drug exposures (barbiturates, sedative-hypnotics)
- Butterfly rash - Systemic lupus erythematosus
- Dark pigmentation - Addison disease
- Edema - Acute renal failure
- Purpura - Meningococcal meningitis, thrombotic thrombocytopenic purpura, vasculitis, disseminated intravascular coagulation, aspirin intoxication
- Rash - Meningitis, viral encephalitis, rickettsia infection, drug ingestion (alcohol, amphetamines, cocaine, ethylene glycol, arsenic, cyclic antidepressants, phencyclidine, phenothiazine)
- Cold, malar flush, yellow tinge, puffy face - Myxedema coma

## LEVEL OF CONSCIOUSNESS

- Glasgow Coma Scale (GCS) is most commonly used
- Other scores such as the FOUR score are used to assess patients with low GCS as it also accounts brainstem reflexes, intubation, use of sedatives or paralytic drugs.

## PATTERN OF BREATHING

Breathing pattern is often forgotten in intubated patients, but is important as the pattern of breathing correlates with the level of the lesion, and may suggest other causes

- Cheyne-Stokes respiration (not specific) - Crescendo-decrescendo breathing pattern followed by apnea or hypopnea; persists in sleep. Seen in Bihemispheric (unilateral or bilateral) or brainstem lesions.
- Central hyperventilation - Sustained hyperventilation, respiratory rates exceeding 40 per minute, seen in Bihemispheric, pons, midbrain lesions
- Irregular ataxic breathing - Irregular respiratory rate, rhythm; amplitudes interrupted by apnea, indicates various brainstem lesion
- Cluster - Irregular clusters of breaths followed by apneic periods of variable duration, Bihemispheric or pons lesions
- Apneustic - Prolonged inspiration with a 2- to 3-s

pause, then expiration, seen in lesions of lateral tegmentum of lower pons

- Also look for deep rapid Kussmaul breathing, secondary to a metabolic acidosis, as in diabetes ketoacidosis

## PUPILLARY RESPONSES

Assess the pupils for size, asymmetry and reactivity to light. Different sized pupils correspond to different types of lesions

- Pinpoint pupils (<2mm) occur in pontine lesions and certain overdoses (e.g. Opioid, Organophosphorus, clonidine)
- Fixed mid-sized pupils occur in midbrain lesions
- One dilated pupil suggests CN3 compression – e.g. ICH, PCOM aneurysm or raised ICP (parasympathetic nerves are in the superficial parts of the nerve, so tend to be more vulnerable to compressive lesions – ptosis and ‘down and out’ eye positioning tends not to occur due to sparing of the more central motor fibers)
- Dilated pupils - found with anticholinergic syndrome and with amphetamines, cocaine and other sympathomimetic drugs. The absence of large pupils does not exclude any of these drugs as pupil size can be influenced by other co-ingested drugs.

## OCULAR DEVIATION AND DYSCONJUGATE GAZE

Dysconjugate gaze - Most individuals have a degree of exophoria when drowsy for any reason and any underlying strabismus tends to worsen.

### Tonic deviation

- Eyes deviate in the same direction of lesions as in frontal lobe lesions, commonly a stroke. This can also be a result of a Todd’s paralysis following a seizure (whereas during the seizure the eyes deviate in the opposite direction – away from the origin of the ‘irritative’ focus).
- A pontine lesion deviates eyes on the opposite side. ‘Wrong way eyes’ may also be seen in thalamic hemorrhage.
- Lateral gaze deviation from a pontine lesion cannot be overcome by stimulating oculocephalic or oculovestibular reflexes (see below), whereas supranuclear (e.g. frontal lesions) can. Hence they can be distinguished clinically.

### Skew deviation

- Vertical separation of the ocular axes is called skew deviation
- This is suggestive of a pontine or vestibulo-cerebellar lesion on the side of the inferior eye, or a medial longitudinal fasciculus lesion on the side of the superior eye

Abnormal eye position can also result from cranial nerve

**1096** palsies (CN6 is particularly at risk due to its long course) and orbital entrapment in trauma

### SPONTANEOUS EYE MOVEMENTS

- Periodic alternating gaze - lateral deviation every few minutes, left and right - Bihemispheric, midbrain, vermis
- Ping-pong - lateral deviation every few seconds, left and right - Bihemispheric, vermis
- Convergence nystagmus - bilateral abduction, slow with rapid jerk back – Mesencephalon
- Bobbing - rapid down, slow up – Pontine lesion
- Dipping -slow down, rapid up – Bihemispheric lesion

### FUNDOSCOPY

Important findings include:

- Papilloedema – optic disc swelling due to raised intracranial pressure. However, the absence of papilloedema does not rule out intracranial hypertension.
- Evidence of Terson syndrome – vitreous, subhyaloid, or retinal bleeding in association with subarachnoid hemorrhage

### OCULOVESTIBULAR REFLEXES

#### Oculocephalic reflex ('doll's eye' reflex)

- Ensure the C-spine is cleared
- The patient's eyes are held open
- The head is briskly turned from side to side with the head held briefly at the end of each turn
- A positive response occurs when the eyes rotate to the opposite side to the direction of head rotation, thus indicating that the brainstem (CN3,6,8) is intact
- A similar result is seen when the head is flexed and extended – a positive result is downward deviation of the eyes during extension, and upward deviation during flexion (the eyelids, if closed, may also open as part of the 'doll's head phenomenon'). These vertical responses indicate that the brainstem (CN3,4,8) is intact
- The eyes should gradually return to the mid-position in a smooth, conjugate movement if the brainstem is intact
- Patients with metabolic coma (e.g. hepatic failure) may have exaggerated, brisk oculocephalic reflexes

#### Oculovestibular reflex (caloric stimulation)

- The head is elevated to 30 degrees above horizontal so that the lateral semicircular canal is vertical, and so that stimulation will generate a maximal response
- Check that the tympanum is intact and that the external ear canal is clear – C-spine clearance is

not necessary

- Introduce iced water into the external ear canal through a small catheter until one of the following occurs:
  - nystagmus (in the intact brainstem the slow phase is towards the irrigated ear)
  - ocular deviation
  - 200mL of iced water has been instilled
- Allow 5 minutes between testing ears to allow re-equilibration of the oculovestibular system
- As consciousness is lost, the fast component (towards the non-irrigated ear) is lost and the slow component tonically deviates the eye in the direction of the irrigated ear

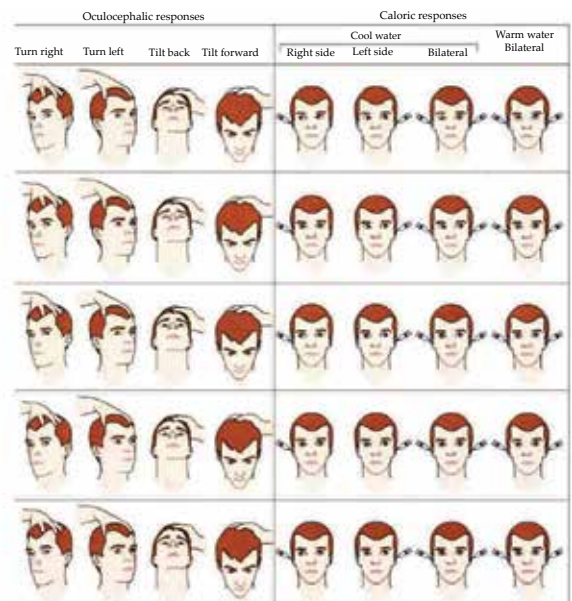
Vertical oculo-vestibular eye responses can be assessed by irrigated both ears simultaneously

- If the brainstem is intact, cold water causes the eyes to deviate downwards and warm water causes the eyes to deviate upwards

### Caveats

- Brainstem encephalitis, deep metabolic coma and certain drugs may mimic brainstem death
- Drugs include recently administered antiepileptics such as phenytoin and barbiturates. Like phenytoin, tricyclic overdose may cause bilateral vestibular failure, as might aminoglycoside vestibulotoxicity. Baclofen overdose can also mimic brain death
- Another caveat pertains to the trauma patient – ocular movements may be impaired if a blowout fracture has trapped the extraocular muscles

Typical findings for various lesions are shown in this figure:



### CORNEAL REFLEX

Corneal reflex is of limited use

- Patients that chronically wear contact lenses may have diminished corneal reflexes
- Loss of the corneal reflex is usually a late sign in coma

### Assessment

- Traditional method is to stroke the cornea with cotton wool
- Corneal stimulation can also be performed by dropping a few drops of sterile saline onto the cornea from a height of 10 cm (less traumatic)
- Reflex is present and intact if the patient blinks and eyes roll upwards
- Afferent: CN5
- Efferent: CN7 (blink) and CN3 (eye movement)
- Indicates that the pons and midbrain are intact (the reflex pathway involves the trigeminal nerve, the spinal CN5 nucleus, the lateral brainstem tegmentum, and the CN3 and CN7 nuclei)
- If the eye turns upwards but the eyelid does not close there is a CN7 lesion (Bell's phenomenon)
- If the eye does not turn upwards and the eyelid does not close there is a CN5 lesion

### GAG AND COUGH REFLEXES

#### Gag reflex

- Sensory = CN9, motor = CN10
- May be absent in normal people and those accustomed to an endotracheal tube
- Best assessed using a laryngoscope or a tongue depressor, look for bilateral palatal elevation

#### Cough reflex

- mediated by CN10
- can be stimulated by a suction catheter down and endotracheal tube

### MOTOR RESPONSES

Posturing can occur spontaneously or in response to a stimulus

- Abnormal flexion is decorticate posturing — adduction of arm, internal rotation of shoulder, pronation of forearm, flexion of wrist (lower limbs are extended); indicates a lesion above the brainstem
- Extension is decerebrate posturing — abduction of arm, external rotation of shoulder, supination of forearm, extension of wrist (lower limbs are extended); indicates a lesion extending to the midbrain or below

#### Assess for:

- tone
- clonus
- deep tendon reflexes
- plantar reflexes
- involuntary movements (such as subtle signs of seizures and myoclonus)

#### Look for asymmetry

Being the first one to find a patient with an acute alteration in consciousness can be a frightening experience. Your immediate actions and skilled assessments may literally save his life.

### JOURNAL ARTICLES

- Wijdicks EF, et al. FOUR score and Glasgow Coma Scale in predicting outcome of comatose patients: a pooled analysis. *Neurology* 2011; 77:84–85
- Walker MC, O'Brien MD. Neurological examination of the unconscious patient. *JR Soc Med* 1999; 92:353-5.

### TEXTBOOKS

- Brazis, Paul W et al . Localization in clinical neurology (5th edition). Lippincott Williams and Wilkins, 2007
- Bersten AD, Soni N. Oh's Intensive Care Manual (6th edition). Butterworth-Heinemann, 2008.
- Poser JB, et al. Plum and Posner's Diagnosis of Stupor and Coma (4th edition), Oxford university Press, 2007.